

Technical Support Center: 18F-FDG Imaging in Inflammatory Conditions

Author: BenchChem Technical Support Team. **Date:** December 2025

Compound of Interest

Compound Name: Fluorodeoxyglucose F 18

Cat. No.: B1208095

[Get Quote](#)

This technical support center provides troubleshooting guides and frequently asked questions (FAQs) to address common challenges encountered during 18F-FDG PET/CT imaging for inflammatory conditions. The information is tailored for researchers, scientists, and drug development professionals to aid in experimental design, execution, and data interpretation.

Frequently Asked Questions (FAQs) & Troubleshooting Guides

Q1: How can I differentiate 18F-FDG uptake in inflammatory lesions from that in malignant tumors?

A1: Distinguishing inflammation from malignancy is a primary challenge in 18F-FDG PET/CT imaging due to the shared mechanism of increased glucose metabolism in both activated immune cells and cancer cells.^{[1][2][3]} While no single method is foolproof, several strategies can be employed:

- **Dual-Time-Point Imaging:** This technique involves acquiring a second scan at a later time point (e.g., 90-120 minutes post-injection) after the initial scan (e.g., 45-60 minutes). Generally, malignant lesions tend to show increasing 18F-FDG uptake over time, while inflammatory lesions often exhibit stable or decreasing uptake.^{[1][4][5]} However, the reliability of this method can be variable, and it has not been universally adopted for routine clinical use.^[1]

- **Dynamic Whole-Body PET:** This advanced technique measures the rate of irreversible ^{18}F -FDG uptake (K_i). Some studies suggest that K_i values may be higher in malignant lesions compared to inflammatory ones, although significant overlap can still exist.[\[6\]](#)
- **Anatomical Correlation with CT/MRI:** Careful examination of the co-registered CT or MRI images is crucial. The location, shape, and characteristics of the underlying tissue can provide contextual clues to differentiate between a tumor and an inflammatory process.[\[1\]](#)
- **Clinical Context:** The patient's clinical history, symptoms, and other biomarker data are invaluable in the interpretation of ^{18}F -FDG PET/CT scans.[\[1\]](#)

Q2: What is the cause of high ^{18}F -FDG uptake in the neck, supraclavicular, and paraspinal regions, and how can it be mitigated?

A2: High ^{18}F -FDG uptake in these regions is often due to the presence of brown adipose tissue (BAT), also known as "USA-Fat" (uptake in supraclavicular area fat).[\[7\]](#)[\[8\]](#) BAT is physiologically activated by cold exposure and sympathetic nervous system stimulation, leading to increased glucose metabolism.[\[7\]](#)[\[8\]](#) This can be a significant confounder in studies of vasculitis or other inflammatory conditions in these anatomical locations.

Troubleshooting Strategies:

- **Patient Preparation:** Keep the patient warm before and after ^{18}F -FDG injection. The waiting room should be comfortably heated.[\[9\]](#)
- **Dietary Modifications:** A low-carbohydrate, high-fat, protein-permitted diet for 24 hours before the scan can help suppress BAT activity.[\[10\]](#)[\[11\]](#)[\[12\]](#)
- **Pharmacological Intervention:** In some cases, premedication with drugs like diazepam or propranolol has been explored to reduce BAT uptake, although their use is not standard practice and should be carefully evaluated.[\[7\]](#)[\[8\]](#) Diazepam has shown mixed results, while propranolol and reserpine have been effective in animal studies.[\[7\]](#)[\[8\]](#)

Q3: How do blood glucose levels affect ^{18}F -FDG uptake in inflammatory lesions, and what are the recommended levels?

A3: High blood glucose levels can competitively inhibit the uptake of 18F-FDG by cells, potentially leading to false-negative results.[13]

- Mechanism: 18F-FDG and glucose compete for the same glucose transporters (GLUTs) on the cell membrane.[13] Elevated serum glucose can saturate these transporters, reducing the amount of 18F-FDG that enters the cell.
- Recommendations: For optimal and consistent results in vascular inflammation imaging, it is recommended to have pre-scan blood glucose levels below 7.0 mmol/L (126 mg/dL).[14][15] While some studies suggest that moderate hyperglycemia may not significantly impact the detection of infection and inflammation, maintaining lower glucose levels is generally advised for standardization.[13][15] Interestingly, one study found that while FDG uptake in malignant lesions was negatively correlated with blood glucose levels, uptake in inflammatory lesions showed a positive association.[16]

Q4: What is the optimal patient preparation protocol to minimize physiological myocardial 18F-FDG uptake for imaging cardiac or vascular inflammation?

A4: Suppressing the physiological glucose uptake of the myocardium is critical for imaging inflammatory conditions like myocarditis, sarcoidosis, or coronary vasculitis.[17][18] The goal is to shift myocardial metabolism from glucose to free fatty acids.

Recommended Protocol:

- Diet: A strict high-fat, high-protein, very-low-carbohydrate (ketogenic) diet for at least 24 to 72 hours prior to the scan.[17][19] Longer durations of the ketogenic diet are associated with better myocardial suppression.[17]
- Fasting: A prolonged fast of 12-18 hours immediately before the scan.[19]
- Heparin Administration: In some protocols, unfractionated heparin may be administered 15 minutes before 18F-FDG injection to increase plasma free fatty acid levels, further promoting their use by the myocardium over glucose.
- Monitoring: Measuring beta-hydroxybutyrate (BHB) levels, a ketone body, prior to imaging can be a useful quality control step to confirm a state of ketosis and predict adequate myocardial suppression.[17][19]

Quantitative Data Summary

The following tables summarize key quantitative parameters from literature to aid in data interpretation.

Table 1: Differentiating Malignant and Inflammatory Lesions with Dual-Time-Point Imaging

| Lesion Type | Change in SUV from Early to Delayed Scan | Reference |
|-------------------------------------|--|-----------|
| Malignant Lesions | Increased (+19.18% \pm 9.58%) | [5] |
| Inflammatory Lesions (animal model) | Decreased (-17% \pm 13%) | [5] |
| Benign Lung Nodules | Slightly Decreased (-6.3% \pm 8.1%) | [5] |
| Radiation-Induced Inflammation | Stable (+1.16% \pm 7.23%) | [5] |

Table 2: Impact of Patient Preparation on Physiological ^{18}F -FDG Uptake

| Preparation Method | Effect on Myocardial Uptake | Effect on Brown Adipose Tissue (BAT) Uptake | Reference |
|-----------------------------------|--|---|-----------|
| Fasting Only | Insufficient suppression | Variable | [10][17] |
| Low-Carbohydrate, High-Fat Diet | Significantly lower uptake vs. fasting | Significantly lower uptake vs. fasting | [10] |
| Ketogenic Diet (≥ 24 hours) | Effective suppression (81-84%) | Not specifically addressed | [17] |
| Ketogenic Diet (72 hours) | High suppression rate (up to 95%) | Not specifically addressed | [17][19] |

Table 3: Influence of Imaging Parameters on Vascular Wall ^{18}F -FDG Uptake

| Parameter | Impact on Aortic/Carotid SUVmax | Impact on Aortic/Carotid TBRmax | Reference |
|------------------------|---------------------------------|---------------------------------|-----------|
| FDG Circulation Time | Negative association | Positive correlation | [14] |
| Pre-scan Blood Glucose | Negative association (carotid) | Negative association | [14] |
| Injected FDG Dose | No significant association | No significant association | [14] |

SUVmax: Maximum Standardized Uptake Value; TBRmax: Maximum Target-to-Background Ratio.

Experimental Protocols & Methodologies

Protocol 1: Dual-Time-Point 18F-FDG PET/CT for Differentiation of Lesions

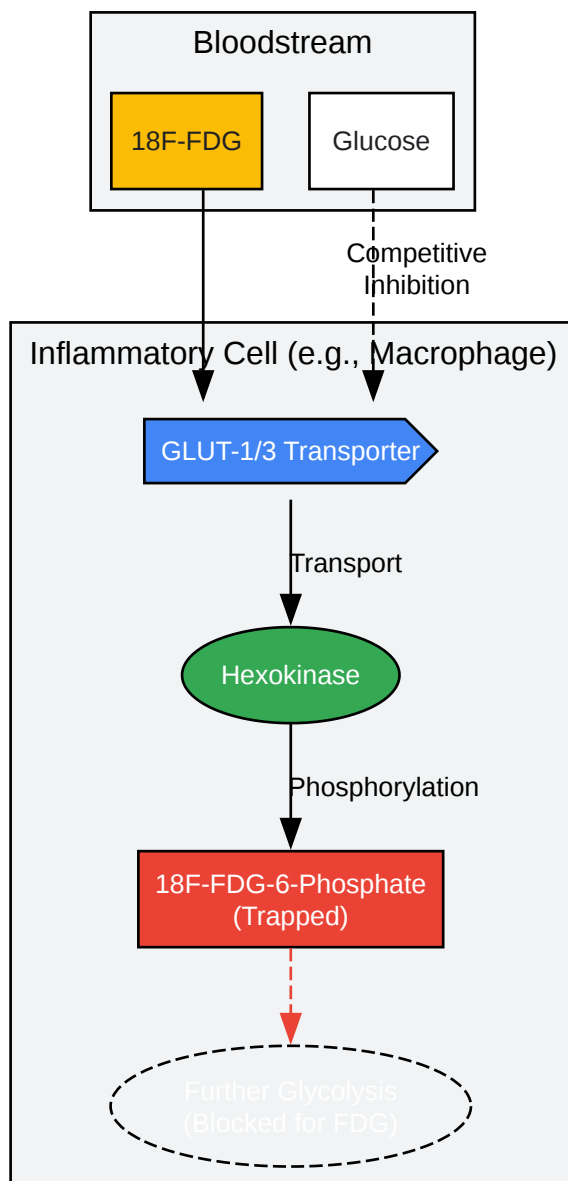
- Patient Preparation: Follow standard oncologic preparation (fasting for at least 4-6 hours, blood glucose < 200 mg/dL).
- 18F-FDG Injection: Administer weight-based dose of 18F-FDG intravenously.
- Uptake Period 1: Patient rests in a quiet, warm room for 45-60 minutes.
- Imaging 1 (Early): Perform a whole-body PET/CT scan.
- Uptake Period 2: Patient continues to rest for an additional 30-60 minutes.
- Imaging 2 (Delayed): Perform a second PET/CT scan, typically over the same anatomical region of interest.
- Analysis: Draw regions of interest (ROIs) over the lesion on both early and delayed images. Calculate the maximum or mean SUV for each. Determine the percentage change in SUV between the two time points.

Protocol 2: Patient Preparation for Myocardial Inflammation Imaging

- **Dietary Regimen:** For 72 hours prior to the imaging session, the patient consumes a high-fat, high-protein, very-low-carbohydrate diet. Prohibited foods include sugars, breads, pastas, rice, grains, and fruits. Permitted foods include meats, fish, eggs, cheese, avocados, and non-starchy vegetables.
- **Fasting:** The patient fasts for a minimum of 12 hours prior to the scheduled 18F-FDG injection time. Only water is permitted.
- **Pre-injection Check:** On the day of the scan, check the patient's blood glucose level. If levels are too high, the scan may need to be rescheduled. Consider measuring blood beta-hydroxybutyrate (BHB) levels to confirm ketosis.[\[17\]](#)
- **18F-FDG Injection & Uptake:** Administer 18F-FDG. The patient should rest in a quiet, comfortable setting for the 60-90 minute uptake period.
- **Imaging:** Perform PET/CT imaging centered on the thorax.

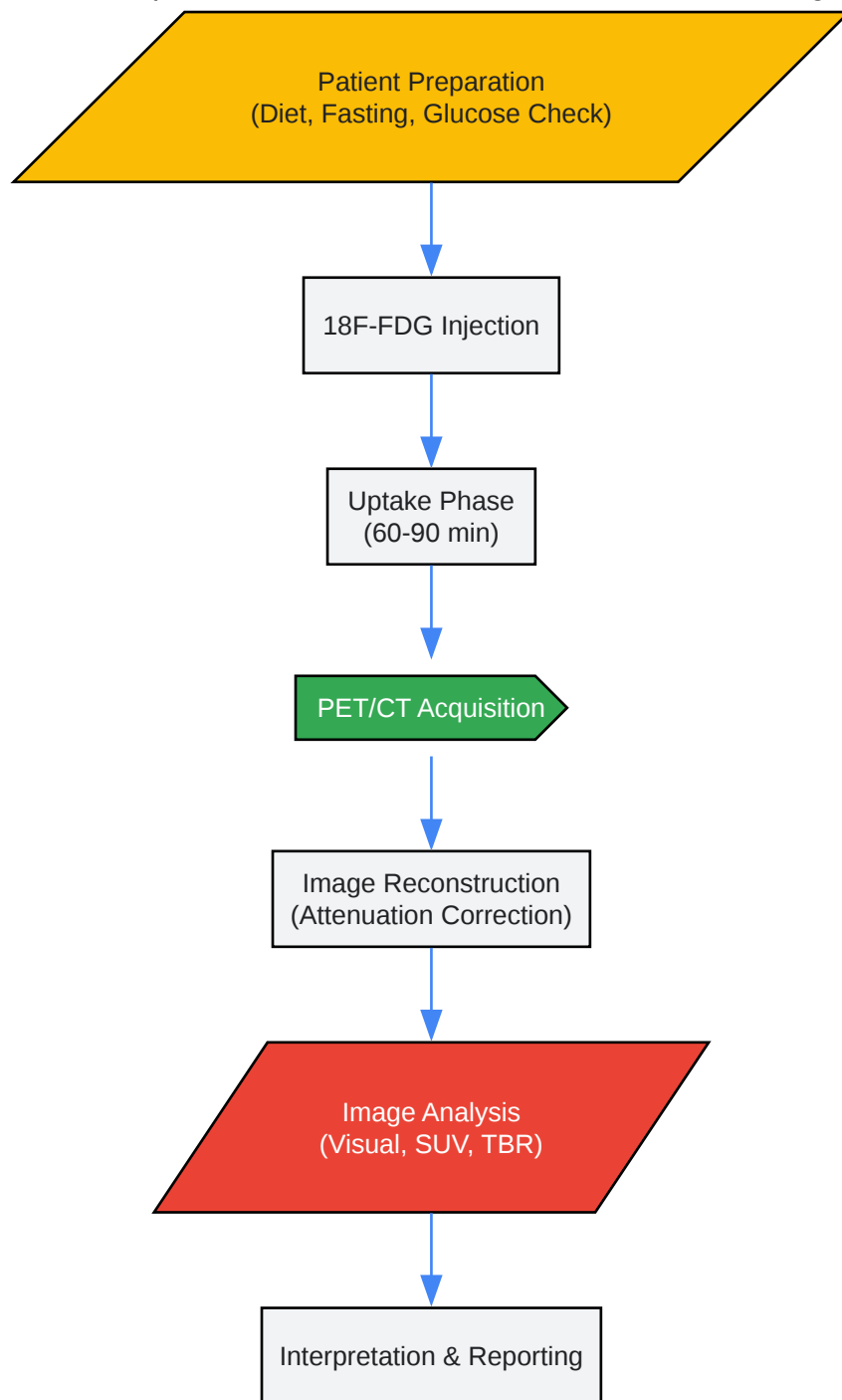
Visualizations

18F-FDG Uptake Mechanism in Inflammatory Cells

[Click to download full resolution via product page](#)

Caption: Mechanism of ^{18}F -FDG uptake and metabolic trapping in an inflammatory cell.

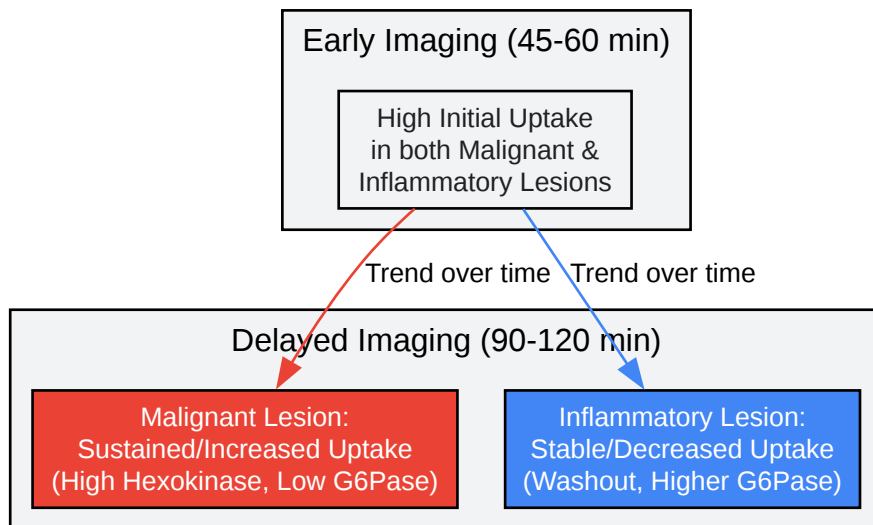
General Experimental Workflow for Inflammation PET Imaging



[Click to download full resolution via product page](#)

Caption: Standardized workflow for an 18F-FDG PET/CT study in inflammation.

Logic of Dual-Time-Point Imaging



[Click to download full resolution via product page](#)

Caption: Differentiating lesions based on ^{18}F -FDG kinetics over time.

Need Custom Synthesis?

BenchChem offers custom synthesis for rare earth carbides and specific isotopic labeling.

Email: info@benchchem.com or [Request Quote Online](#).

References

- 1. scienceopen.com [scienceopen.com]
- 2. Dynamic FDG-PET Imaging to Differentiate Malignancies from Inflammation in Subcutaneous and In Situ Mouse Model for Non-Small Cell Lung Carcinoma (NSCLC) - PMC [pmc.ncbi.nlm.nih.gov]
- 3. Frontiers | ^{18}F -FDG PET/CT Imaging: Normal Variants, Pitfalls, and Artifacts Musculoskeletal, Infection, and Inflammation [frontiersin.org]
- 4. jnm.snmjournals.org [jnm.snmjournals.org]
- 5. Dual time point ^{18}F -FDG PET imaging for differentiating malignant from inflammatory processes - PubMed [pubmed.ncbi.nlm.nih.gov]
- 6. mdpi.com [mdpi.com]

- 7. jnm.snmjournals.org [jnm.snmjournals.org]
- 8. Intense (18)F-FDG uptake in brown fat can be reduced pharmacologically - PubMed [pubmed.ncbi.nlm.nih.gov]
- 9. cme.lww.com [cme.lww.com]
- 10. Preparation methods prior to PET/CT scanning that decrease uptake of 18F-FDG by myocardium, brown adipose tissue, and skeletal muscle - PubMed [pubmed.ncbi.nlm.nih.gov]
- 11. Method for decreasing uptake of 18F-FDG by hypermetabolic brown adipose tissue on PET - PubMed [pubmed.ncbi.nlm.nih.gov]
- 12. ajronline.org [ajronline.org]
- 13. jnm.snmjournals.org [jnm.snmjournals.org]
- 14. Optimizing 18F-FDG PET/CT Imaging of Vessel Wall Inflammation –The Impact of 18F-FDG Circulation Time, Injected Dose, Uptake Parameters, and Fasting Blood Glucose Levels - PMC [pmc.ncbi.nlm.nih.gov]
- 15. tech.snmjournals.org [tech.snmjournals.org]
- 16. Do high glucose levels have differential effect on FDG uptake in inflammatory and malignant disorders? - PubMed [pubmed.ncbi.nlm.nih.gov]
- 17. How to prepare a patient for 18F-fluorodeoxyglucose positron emission tomography imaging to assess myocardial inflammation - PMC [pmc.ncbi.nlm.nih.gov]
- 18. Novel Positron Emission Tomography Tracers for Imaging Vascular Inflammation - PMC [pmc.ncbi.nlm.nih.gov]
- 19. researchgate.net [researchgate.net]
- To cite this document: BenchChem. [Technical Support Center: 18F-FDG Imaging in Inflammatory Conditions]. BenchChem, [2025]. [Online PDF]. Available at: [<https://www.benchchem.com/product/b1208095#overcoming-challenges-of-18f-fdg-imaging-in-inflammatory-conditions>]

Disclaimer & Data Validity:

The information provided in this document is for Research Use Only (RUO) and is strictly not intended for diagnostic or therapeutic procedures. While BenchChem strives to provide accurate protocols, we make no warranties, express or implied, regarding the fitness of this product for every specific experimental setup.

Technical Support: The protocols provided are for reference purposes. Unsure if this reagent suits your experiment? [[Contact our Ph.D. Support Team for a compatibility check](#)]

Need Industrial/Bulk Grade? [Request Custom Synthesis Quote](#)

BenchChem

Our mission is to be the trusted global source of essential and advanced chemicals, empowering scientists and researchers to drive progress in science and industry.

Contact

Address: 3281 E Guasti Rd
Ontario, CA 91761, United States
Phone: (601) 213-4426
Email: info@benchchem.com