

Common pitfalls in the interpretation of "Choline C-11" PET/CT scans

Author: BenchChem Technical Support Team. **Date:** December 2025

Compound of Interest

Compound Name: Choline C-11

Cat. No.: B1203964

[Get Quote](#)

Technical Support Center: Interpreting Choline C-11 PET/CT Scans

This technical support center provides troubleshooting guides and frequently asked questions (FAQs) to assist researchers, scientists, and drug development professionals in accurately interpreting **Choline C-11** PET/CT scan results.

Frequently Asked Questions (FAQs)

Q1: What are the most common causes of false-positive results in **Choline C-11** PET/CT scans for prostate cancer?

A1: False-positive findings in **Choline C-11** PET/CT for prostate cancer can be attributed to several benign conditions that also exhibit increased choline metabolism. It is crucial to consider these potential pitfalls to avoid misinterpretation.

- Benign Prostatic Hyperplasia (BPH): BPH is a frequent cause of increased **Choline C-11** uptake, and there can be a significant overlap in standardized uptake values (SUV) between BPH and prostate cancer tissue.[\[1\]](#)[\[2\]](#)[\[3\]](#)
- Prostatitis: Inflammatory processes within the prostate gland, such as prostatitis, can lead to elevated choline uptake, mimicking malignancy.[\[1\]](#)[\[4\]](#)[\[5\]](#)

- **Post-Biopsy Inflammation:** Reparative changes following a prostate biopsy may cause false-positive choline uptake. It is recommended to have a sufficient time interval between biopsy and the PET/CT scan.[1]
- **Reactive Lymph Nodes:** Inflammation or other benign conditions can cause lymph nodes to show increased choline avidity, which may be mistaken for metastatic disease.[6]

Q2: Can **Choline C-11** PET/CT reliably distinguish between benign prostatic hyperplasia (BPH) and prostate cancer?

A2: Differentiating between BPH and prostate cancer using **Choline C-11** PET/CT can be challenging due to overlapping uptake values.[2][7] Studies have shown that while the mean standardized uptake value (SUV) in prostate cancer tissue is generally higher than in BPH, the difference is not always statistically significant, making definitive diagnosis based on SUV alone difficult.[1][3][8] Some research suggests that combining multiple metabolic parameters, such as SUVmax, SUVmean, and the prostate-to-muscle ratio, may improve diagnostic accuracy.[9]

Q3: What are some common incidental findings on a **Choline C-11** PET/CT scan performed for prostate cancer evaluation?

A3: **Choline C-11** PET/CT scans, often performed as whole-body scans, can reveal unexpected areas of uptake not related to prostate cancer. It is important to be aware of these potential incidentalomas.

- **Meningiomas:** These are the most frequently reported incidental brain findings on **Choline C-11** PET/CT scans.[10][11]
- **Thyroid Nodules:** Focal uptake in the thyroid gland is another common incidental finding.[12][13] While many of these are benign, a small percentage can be malignant, warranting further investigation.[13][14]
- **Other Malignancies:** Although less common, **Choline C-11** PET/CT can incidentally detect other cancers such as lung, breast, or colon cancer.[14]
- **Inflammatory and Benign Conditions:** Various benign lesions and inflammatory processes, like sarcoidosis or nodular fasciitis, can also show increased choline uptake.[15][16]

Q4: How does the Prostate-Specific Antigen (PSA) level impact the interpretation of a **Choline C-11** PET/CT scan for recurrent prostate cancer?

A4: The serum PSA level at the time of the scan is a critical factor influencing the detection rate of recurrent prostate cancer.^{[17][18]} Generally, the likelihood of a positive scan increases with higher PSA levels.^{[6][19]} For patients with very low PSA levels (e.g., <1.0 ng/mL), the detection rate of **Choline C-11** PET is lower.^{[6][19]} This correlation is important to consider when interpreting scan results, especially in cases of biochemical recurrence.

Troubleshooting Guides

Problem 1: Ambiguous focal uptake in the prostate bed post-prostatectomy.

- Possible Cause: This could represent a true local recurrence, but false positives can occur due to post-surgical inflammation or urinary activity.
- Troubleshooting Steps:
 - Correlate with PSA levels: A rising PSA level increases the suspicion of a true recurrence.^[17]
 - Review CT data carefully: Anatomical correlation on the CT component can help differentiate between soft tissue recurrence and other causes.
 - Consider the timing of the scan: Scans performed too soon after surgery may show inflammatory changes.
 - Recommend further imaging: Pelvic MRI or a follow-up PET scan may be warranted to assess for changes over time.

Problem 2: Unexpected focal uptake outside the pelvic region in a patient with prostate cancer.

- Possible Cause: This could be a distant metastasis, a second primary malignancy, or a benign incidental finding.
- Troubleshooting Steps:

- Thoroughly review the patient's clinical history: Look for any symptoms or history related to the site of uptake.
- Analyze the CT characteristics of the lesion: The anatomical features on CT can provide clues to the nature of the finding.
- Consider the pattern of uptake: Metastatic prostate cancer has typical patterns of spread (e.g., bone, lymph nodes).
- Recommend further investigation: Depending on the location and characteristics of the lesion, further imaging (e.g., dedicated CT, MRI) or biopsy may be necessary to confirm the diagnosis.

Data Presentation

Table 1: Quantitative Analysis of ¹¹C-Choline Uptake (SUVmax) in Different Prostatic Tissues

Tissue Type	Mean SUVmax (± SD)	Range of SUVmax	Reference
Prostate Cancer	3.5 (± 1.3)	1.9 - 15.5	[7][8]
Benign Prostatic Hyperplasia (BPH)	2.0 (± 0.6)	2.0 - 4.5	[7][8]
Prostatitis	2.1 (± 0.6)	-	[4]
Normal Prostate Tissue	2.0 (± 0.6)	1.3 - 3.2	[3][8]

Table 2: Detection Rate of Recurrent Prostate Cancer by ¹¹C-Choline PET/CT based on PSA Levels

PSA Level (ng/mL)	Detection Rate (%)	Reference
< 0.5	45	[6]
0.5 - 0.99	56	[6]
1.0 - 1.99	70	[6]
≥ 2.0	90.5	[6]

Experimental Protocols

Protocol 1: Patient Preparation for **Choline C-11** PET/CT Scan

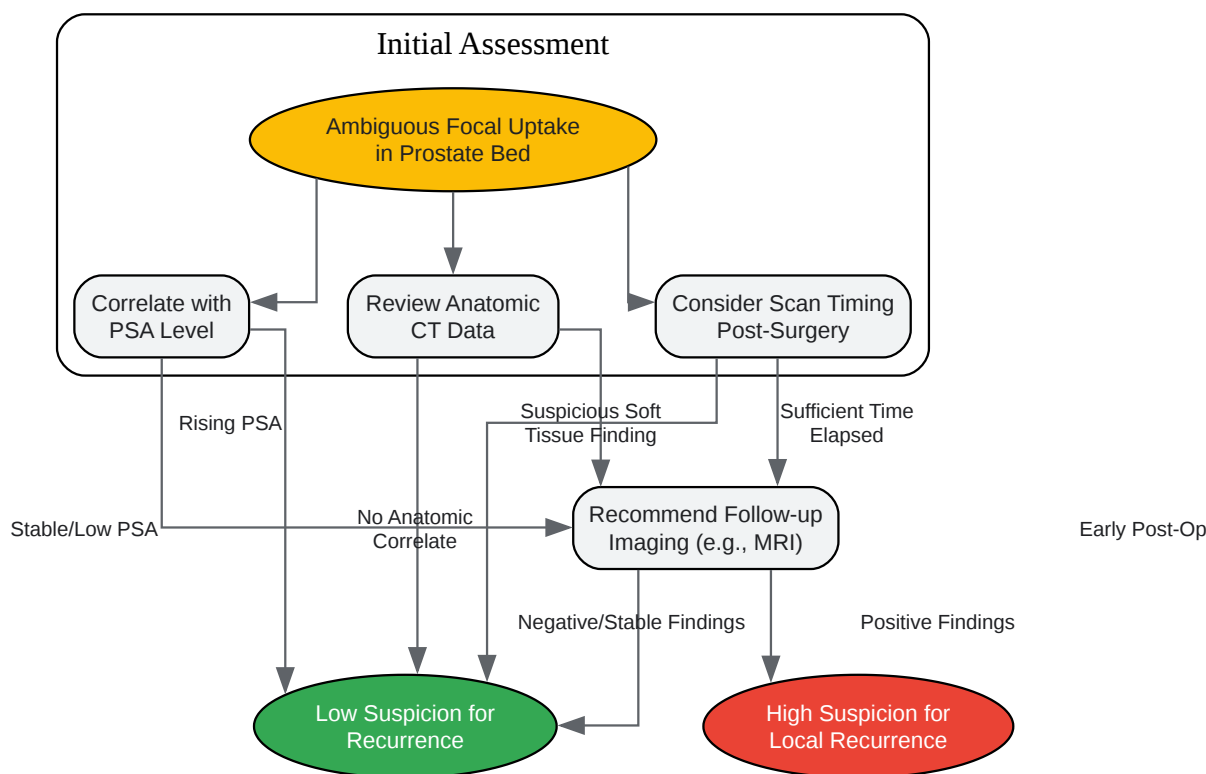
- Fasting: Patients should fast for a minimum of 4-6 hours prior to the scan to minimize background physiological uptake.[1][20]
- Hydration: Patients are encouraged to drink plenty of water before the scan to ensure adequate hydration.[20]
- Medications: Routine medications can generally be taken as prescribed. Diabetic patients may require specific instructions regarding their medication.[21][22]
- Physical Activity: Strenuous physical activity should be avoided for 24 hours before the scan to prevent muscle uptake of the tracer.[22]
- Dietary Restrictions: Some protocols may recommend a low-carbohydrate, high-protein diet for 24 hours preceding the scan.[22][23]

Protocol 2: **Choline C-11** PET/CT Imaging Protocol

- Radiotracer Injection: An intravenous injection of 370-740 MBq (10-20 mCi) of **Choline C-11** is administered.[19]
- Uptake Time: Imaging typically begins 5 minutes after the injection.[1]
- Scanning Range: The scan is usually performed from the base of the skull to the mid-thigh.

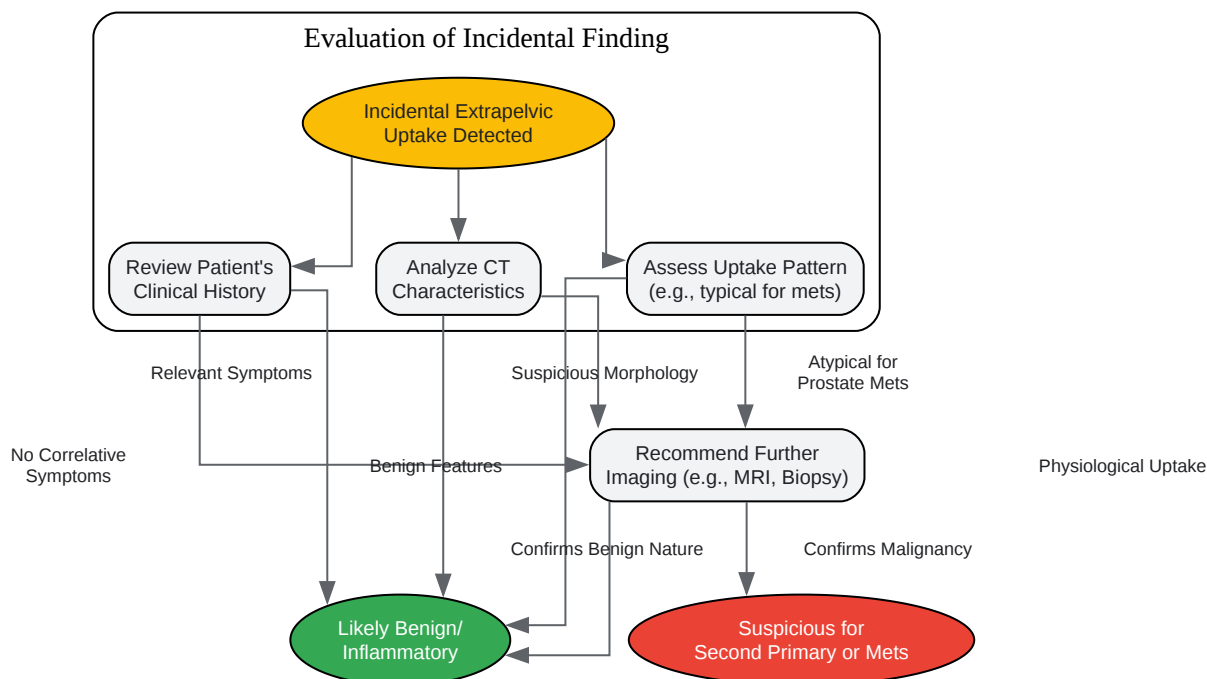
- PET Acquisition: A dynamic PET emission scan of the pelvis may be acquired for the first 5 minutes, followed by static images over the entire scan range.[19]
- CT Acquisition: A low-dose CT scan is performed for attenuation correction and anatomical localization. A diagnostic contrast-enhanced CT may also be acquired.[1]
- Image Reconstruction and Analysis: PET images are reconstructed and co-registered with the CT images. Abnormal focal uptake is identified visually and quantified using Standardized Uptake Values (SUV).[19]

Visualizations



[Click to download full resolution via product page](#)

Caption: Troubleshooting workflow for ambiguous focal uptake in the prostate bed.



[Click to download full resolution via product page](#)

Caption: Decision tree for the management of incidental extrapelvic findings.

Need Custom Synthesis?

BenchChem offers custom synthesis for rare earth carbides and specific isotopic labeling.

Email: info@benchchem.com or [Request Quote Online](#).

References

- 1. aacrjournals.org [aacrjournals.org]
- 2. Imaging primary prostate cancer with ¹¹C-Choline PET/CT: relation to tumour stage, Gleason score and biomarkers of biologic aggressiveness - PMC [pmc.ncbi.nlm.nih.gov]

- 3. Choline PET and PET/CT in Primary Diagnosis and Staging of Prostate Cancer - PMC [pmc.ncbi.nlm.nih.gov]
- 4. jnm.snmjournals.org [jnm.snmjournals.org]
- 5. clinicsinoncology.com [clinicsinoncology.com]
- 6. 11C-Choline PET/CT in Recurrent Prostate Cancer: Retrospective Analysis in a Large U.S. Patient Series - PMC [pmc.ncbi.nlm.nih.gov]
- 7. Kinetics of [(11)C]choline uptake in prostate cancer: a PET study - PubMed [pubmed.ncbi.nlm.nih.gov]
- 8. Imaging Prostate Cancer with 11C-Choline PET/CT | Journal of Nuclear Medicine [jnm.snmjournals.org]
- 9. Value of 11C-Choline PET/CT-Based Multi-Metabolic Parameter Combination in Distinguishing Early-Stage Prostate Cancer From Benign Prostate Diseases - PMC [pmc.ncbi.nlm.nih.gov]
- 10. mdpi.com [mdpi.com]
- 11. Incidental detection by [11C]choline PET/CT of meningiomas in prostate cancer patients - PubMed [pubmed.ncbi.nlm.nih.gov]
- 12. mdpi.com [mdpi.com]
- 13. Risk of malignancy in thyroid nodules with increased 11C-Choline uptake detected incidentally on PET/CT: A diagnostic accuracy study - PubMed [pubmed.ncbi.nlm.nih.gov]
- 14. researchgate.net [researchgate.net]
- 15. PET Scan False Positive Cancer: Causes and How to Avoid Misdiagnosis - Liv Hospital [int.livhospital.com]
- 16. Nodular Fasciitis: False Positive on 18F-Piflufolastat and 11C-Choline PET/CT - PubMed [pubmed.ncbi.nlm.nih.gov]
- 17. Interpretation of 11C–choline PET/CT for the diagnosis of local relapse in radically treated prostate cancer - PMC [pmc.ncbi.nlm.nih.gov]
- 18. PET Scan False Positives: Myths and Realities - Liv Hospital [int.livhospital.com]
- 19. 11C-Choline PET/CT in Recurrent Prostate Cancer: Retrospective Analysis in a Large U.S. Patient Series | Journal of Nuclear Medicine [jnm.snmjournals.org]
- 20. Choline C-11 PET scan - Mayo Clinic [mayoclinic.org]
- 21. PET/CT Scan: How to Prepare, What to Expect & Safety Tips [radiology.ucsf.edu]

- 22. How to Prepare for Your PET/CT Scan - General Directions | Brown University Health [brownhealth.org]
- 23. flcancer.com [flcancer.com]
- To cite this document: BenchChem. [Common pitfalls in the interpretation of "Choline C-11" PET/CT scans]. BenchChem, [2025]. [Online PDF]. Available at: [https://www.benchchem.com/product/b1203964#common-pitfalls-in-the-interpretation-of-choline-c-11-pet-ct-scans]

Disclaimer & Data Validity:

The information provided in this document is for Research Use Only (RUO) and is strictly not intended for diagnostic or therapeutic procedures. While BenchChem strives to provide accurate protocols, we make no warranties, express or implied, regarding the fitness of this product for every specific experimental setup.

Technical Support: The protocols provided are for reference purposes. Unsure if this reagent suits your experiment? [[Contact our Ph.D. Support Team for a compatibility check](#)]

Need Industrial/Bulk Grade? [Request Custom Synthesis Quote](#)

BenchChem

Our mission is to be the trusted global source of essential and advanced chemicals, empowering scientists and researchers to drive progress in science and industry.

Contact

Address: 3281 E Guasti Rd

Ontario, CA 91761, United States

Phone: (601) 213-4426

Email: info@benchchem.com