

# Image artifacts in FDG F18 PET imaging and how to avoid them

**Author:** BenchChem Technical Support Team. **Date:** December 2025

## Compound of Interest

Compound Name: Fluorodeoxyglucose F18

Cat. No.: B1200657

[Get Quote](#)

## Technical Support Center: FDG F18 PET Imaging

This technical support center provides troubleshooting guides and frequently asked questions (FAQs) to help researchers, scientists, and drug development professionals identify and avoid common image artifacts in FDG F18 PET imaging.

## Frequently Asked Questions (FAQs)

Q1: What are the most common image artifacts in FDG F18 PET imaging?

A1: The most frequently encountered artifacts in FDG F18 PET imaging can be broadly categorized as patient-related, scanner-related, or radiopharmaceutical-related. Key examples include:

- Patient-Related Artifacts:
  - Motion Artifacts: Caused by patient movement during the scan, leading to blurred images and inaccurate quantification.[\[1\]](#)[\[2\]](#)
  - Metal Artifacts: Resulting from metallic implants (e.g., dental fillings, prostheses) that can cause streaks and inaccuracies in the PET data due to incorrect attenuation correction.[\[3\]](#)[\[4\]](#)[\[5\]](#)
  - Hyperglycemia: Elevated blood glucose levels can competitively inhibit FDG uptake in tumors, leading to reduced image contrast and lower standardized uptake values (SUVs).

[6][7][8][9]

- Brown Adipose Tissue (BAT) Uptake: Cold exposure can activate brown fat, leading to intense FDG uptake that can mimic malignancy.[10]
- Scanner-Related Artifacts:
  - Attenuation Correction Artifacts: Errors in the CT-based attenuation map can lead to incorrect PET data reconstruction, causing either artificially high or low uptake values.[1][11]
  - Truncation Artifacts: Occur when parts of the body are outside the CT field of view but inside the PET field of view, resulting in inaccurate attenuation correction at the edges of the image.[1][10]
- Radiopharmaceutical-Related Artifacts:
  - Extravasation: Leakage of the FDG tracer at the injection site can lead to localized high uptake and may compromise the quantification of uptake in the region of interest.
  - Radiochemical Impurities: The presence of unbound F18-fluoride or other impurities can affect image quality and biodistribution.

Q2: How can I minimize patient motion during an FDG PET scan?

A2: Minimizing patient motion is critical for high-quality PET images. Strategies include:

- Patient Comfort: Ensure the patient is comfortable before starting the scan. Provide pillows and blankets to help them remain still.
- Clear Instructions: Clearly explain the importance of remaining still throughout the scan to the patient.
- Immobilization Devices: Use head holders, straps, and other immobilization devices, especially for head and neck imaging.[2]
- Scan Duration: Optimize scan protocols to minimize acquisition time without compromising image quality.

- Motion Correction Software: If available, use motion correction software during image reconstruction.

Q3: What is the impact of high blood glucose on FDG PET images and how can it be managed?

A3: High blood glucose (hyperglycemia) can significantly impact FDG PET imaging. Elevated glucose levels in the blood compete with FDG for uptake into cells, which can lead to:

- Decreased tumor-to-background contrast, making it harder to detect tumors.[6]
- Underestimation of the Standardized Uptake Value (SUV), a key quantitative measure of metabolic activity.[7]

Management of Blood Glucose:

- Fasting: Patients should fast for at least 4-6 hours before the scan to lower blood glucose and insulin levels.[12][13]
- Dietary Restrictions: A low-carbohydrate, high-protein diet is often recommended for 24 hours preceding the scan.[13][14]
- Blood Glucose Monitoring: Check the patient's blood glucose level before injecting the FDG tracer. Guidelines often recommend a blood glucose level below 150-200 mg/dL.[7][9]
- Rescheduling: If blood glucose is too high, it is often best to reschedule the scan.[14]

Q4: How do metal implants affect PET images and what can be done to correct for these artifacts?

A4: Metal implants, such as dental fillings or hip prostheses, have high density and can cause significant artifacts on the CT portion of a PET/CT scan. These CT artifacts lead to errors in the attenuation correction map used for the PET data, resulting in:

- Streaks: Bright and dark streaks emanating from the metal implant.[3][5]
- Inaccurate SUV values: Overestimation or underestimation of tracer uptake in tissues near the implant.[3][15][16]

#### Correction Methods:

- **Metal Artifact Reduction (MAR) Software:** Many modern CT scanners are equipped with MAR software that can significantly reduce the artifacts caused by metal implants, leading to improved PET quantification.[\[4\]](#)[\[16\]](#)
- **Review of Non-Attenuation Corrected (NAC) Images:** Examining the NAC PET images can help determine if an area of high uptake is a true finding or an artifact caused by attenuation correction.

## Troubleshooting Guides

### Issue 1: Suspected Motion Artifacts

#### Symptoms:

- Blurred organ boundaries and lesions.
- Misalignment between the PET and CT images.
- Artificially enlarged or distorted lesion shapes.

#### Troubleshooting Steps:

- **Review Cine Images:** If acquired, review the cine (dynamic) images to visually assess patient movement during the scan.
- **Check for PET-CT Misregistration:** Carefully examine the fused PET/CT images for any obvious misalignment between anatomical structures on the CT and areas of FDG uptake on the PET. This is particularly common at the diaphragm.
- **Apply Motion Correction:** If available on your system, re-reconstruct the data using motion correction algorithms.
- **Repeat Scan:** In cases of severe motion, repeating the scan may be necessary.

### Issue 2: Unexpectedly Low Tumor SUV

#### Symptoms:

- Lower than expected SUV values in known or suspected tumors.
- Poor tumor-to-background contrast.

#### Troubleshooting Steps:

- **Check Patient's Blood Glucose Level:** Verify the patient's blood glucose reading taken before the scan. Hyperglycemia is a common cause of reduced tumor FDG uptake.[\[6\]](#)[\[7\]](#)
- **Confirm Fasting Status:** Inquire about the patient's adherence to the fasting protocol.
- **Review Patient Medications:** Certain medications can influence glucose metabolism.
- **Assess for Competing Physiological Uptake:** High uptake in muscles due to recent exercise or in brown adipose tissue from cold exposure can reduce the amount of FDG available for tumor uptake.

## Issue 3: Focal Area of High Uptake in an Unusual Location

#### Symptoms:

- An intense, focal "hot spot" that does not correspond to a known or suspected lesion.

#### Troubleshooting Steps:

- **Check for Extravasation:** Examine the injection site for signs of tracer infiltration into the subcutaneous tissue.
- **Review Non-Attenuation Corrected (NAC) Images:** Compare the attenuation-corrected (AC) and NAC images. If the "hot spot" is significantly less intense or absent on the NAC images, it is likely an attenuation correction artifact.
- **Correlate with CT Anatomy:** Carefully examine the corresponding area on the CT image to see if there is a high-density object (e.g., metal implant, oral contrast) that could be causing an artifact.[\[11\]](#)

- Consider Physiological Variants: Be aware of normal physiological FDG uptake in areas like the salivary glands, thymus, and urinary tract, which can sometimes be intense.

## Quantitative Data Summary

The following table summarizes the quantitative impact of various artifacts on SUV measurements and the effectiveness of corresponding correction methods.

Artifact Type	Quantitative Impact on SUV	Correction Method	Quantitative Improvement with Correction
Metal Artifacts	Overestimation or underestimation of SUV, with errors ranging from 2% to over 30%. <a href="#">[3]</a> <a href="#">[15]</a>	Iterative Metal Artifact Reduction (iMAR) Software	iMAR can significantly reduce SUV errors, with reported decreases of up to 82.4% in overestimated SUVmax and increases of up to 90.5% in underestimated SUVmax in artifact-affected regions. <a href="#">[16]</a>
Respiratory Motion	Underestimation of SUVmax by up to 30% or more and overestimation of tumor volume by a factor of two or more. <a href="#">[17]</a> For smaller lesions (1 cm), SUVmax can be underestimated by a mean of 28%. <a href="#">[18]</a>	Respiratory Gating / Motion Correction	Motion correction techniques can lead to a 10-30% increase in measured tumor SUVmax. <a href="#">[17]</a> <a href="#">[19]</a> One study showed a mean SUVmax increase of $(10 \pm 10)\%$ . <a href="#">[17]</a>

Hyperglycemia	Inverse relationship between blood glucose levels and brain SUV.[6][7] A blood glucose level of 201 mg/dL and above can lead to at least a 65% reduction in normal brain FDG uptake.[7]	Strict Patient Preparation (Fasting)	Adherence to fasting protocols aims to bring blood glucose into the optimal range (<150-200 mg/dL) to minimize competitive inhibition.
---------------	---	--------------------------------------	--

## Experimental Protocols

### Protocol 1: Standard Patient Preparation for FDG PET/CT

This protocol is designed to minimize physiological variations in FDG uptake.

#### 1. Patient Scheduling and Pre-Scan Instructions:

- Inquire about any history of diabetes and current medications.
- Instruct the patient to follow a low-carbohydrate, high-protein diet for 24 hours prior to the scan.[13][14]
- Advise the patient to avoid strenuous exercise for at least 24 hours before the scan.[12][20]
- Instruct the patient to fast for a minimum of 6 hours before the scheduled appointment time. Only plain water is permitted.[12][13]

#### 2. On the Day of the Scan:

- Confirm the patient has followed all pre-scan instructions.
- Measure the patient's blood glucose level. If the level is above 200 mg/dL, consult with the supervising physician; the scan may need to be rescheduled.[9]
- Encourage the patient to drink water to ensure good hydration.[12]
- Place the patient in a quiet, dimly lit, and warm room to minimize muscle and brown fat activation.[10]

#### 3. FDG Injection and Uptake Phase:



- Administer the FDG F18 injection intravenously.
- The patient should rest quietly for the uptake period, typically 60 minutes. Talking, reading, or using electronic devices should be avoided.[\[21\]](#)

#### 4. Imaging:

- Ask the patient to void their bladder immediately before the scan.[\[20\]](#)
- Position the patient on the scanner bed, ensuring they are as comfortable as possible to minimize motion. Use immobilization aids as needed.

## Protocol 2: Quality Control of F18-FDG Radiopharmaceutical

This protocol outlines the essential quality control tests to be performed on the F18-FDG radiopharmaceutical before administration.

#### 1. Visual Inspection:

- Visually inspect the F18-FDG solution behind appropriate shielding.
- Acceptance Criteria: The solution must be clear, colorless, and free of any particulate matter.

#### 2. Radionuclidic Identity:

- Measure the half-life of the radionuclide.
- Place a sample of the F18-FDG in a dose calibrator and record the activity and time.
- After a set period (e.g., 20-30 minutes), remeasure the activity and record the time.
- Calculate the half-life.
- Acceptance Criteria: The calculated half-life should be between 105 and 115 minutes for Fluorine-18.

#### 3. Radiochemical Purity:

- Determine the percentage of F18-FDG relative to other radioactive compounds.
- This is typically performed using thin-layer chromatography (TLC) or high-performance liquid chromatography (HPLC).[\[22\]](#)
- For TLC, spot the F18-FDG sample on a TLC plate and develop it in a suitable mobile phase (e.g., acetonitrile:water 95:5).[\[22\]](#)
- Acceptance Criteria: The radiochemical purity should be  $\geq 95\%$ .

#### 4. pH:

- Measure the pH of the F18-FDG solution using a calibrated pH meter or pH strips.
- Acceptance Criteria: The pH should be between 4.5 and 7.5.

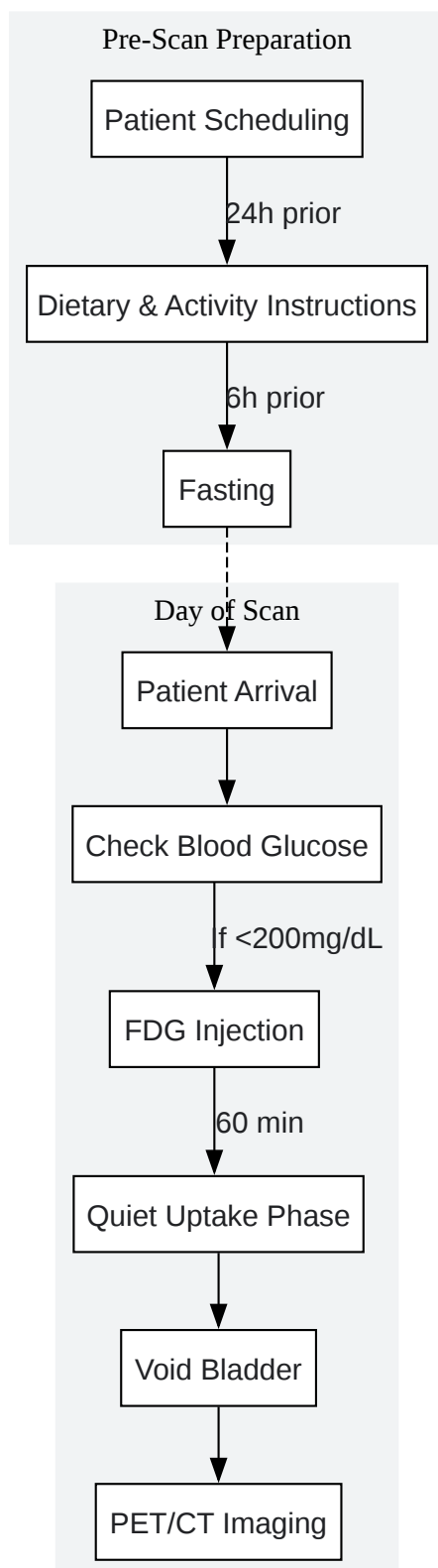
#### 5. Bacterial Endotoxin Test:

- Perform a Limulus Amebocyte Lysate (LAL) test to detect the presence of bacterial endotoxins.
- Acceptance Criteria: The endotoxin level must be below the established limit (e.g.,  $< 175$  EU/V, where V is the maximum recommended dose in mL).

#### 6. Sterility:


- Test for the presence of viable microorganisms. This is typically a retrospective test, with the dose being released before the results are available.
- A filter integrity test provides an indirect measure of sterility before dose release.
- Acceptance Criteria: No microbial growth.

## Visualizations



[Click to download full resolution via product page](#)

Caption: Experimental Workflow for Patient Preparation in FDG PET/CT.



[Click to download full resolution via product page](#)

Caption: Logical Workflow for Troubleshooting Image Artifacts.

#### Need Custom Synthesis?

BenchChem offers custom synthesis for rare earth carbides and specific isotopic labeling.

Email: [info@benchchem.com](mailto:info@benchchem.com) or [Request Quote Online](#).

## References

- 1. researchgate.net [researchgate.net]
- 2. tech.snmjournals.org [tech.snmjournals.org]
- 3. jnm.snmjournals.org [jnm.snmjournals.org]
- 4. Value of CT iterative metal artifact reduction in PET/CT—clinical evaluation in 100 patients - PMC [pmc.ncbi.nlm.nih.gov]
- 5. mdpi.com [mdpi.com]
- 6. Effect of hyperglycemia on brain and liver 18F-FDG standardized uptake value (FDG SUV) measured by quantitative positron emission tomography (PET) imaging - PMC [pmc.ncbi.nlm.nih.gov]
- 7. tech.snmjournals.org [tech.snmjournals.org]
- 8. 18F-FDGPET/CT: diabetes and hyperglycaemia | Niccoli-Asabella | Nuclear Medicine Review [journals.viamedica.pl]

- 9. Effects of hyperglycemia on fluorine-18-fluorodeoxyglucose biodistribution in a large oncology clinical practice - PubMed [pubmed.ncbi.nlm.nih.gov]
- 10. cme.lww.com [cme.lww.com]
- 11. PET/CT Artifacts - PMC [pmc.ncbi.nlm.nih.gov]
- 12. tech.snmjournals.org [tech.snmjournals.org]
- 13. tech.snmjournals.org [tech.snmjournals.org]
- 14. Instructions for PET Scans | CARTI Cancer Center [carti.com]
- 15. Quantitative Effect of Metal Artefact Reduction on CT-based attenuation correction in FDG PET/CT in patients with hip prosthesis - PMC [pmc.ncbi.nlm.nih.gov]
- 16. Impact of different metal artifact reduction techniques on attenuation correction in 18F-FDG PET/CT examinations - PMC [pmc.ncbi.nlm.nih.gov]
- 17. Respiratory motion correction for quantitative PET/CT using all detected events with internal—external motion correlation - PMC [pmc.ncbi.nlm.nih.gov]
- 18. The impact of respiratory motion on tumor quantification and delineation in static PET/CT imaging - PMC [pmc.ncbi.nlm.nih.gov]
- 19. researchgate.net [researchgate.net]
- 20. FDG PET/CT: EANM procedure guidelines for tumour imaging: version 2.0 - PMC [pmc.ncbi.nlm.nih.gov]
- 21. svhs.org.au [svhs.org.au]
- 22. Review of 18F-FDG Synthesis and Quality Control - PMC [pmc.ncbi.nlm.nih.gov]
- To cite this document: BenchChem. [Image artifacts in FDG F18 PET imaging and how to avoid them]. BenchChem, [2025]. [Online PDF]. Available at: [https://www.benchchem.com/product/b1200657#image-artifacts-in-fdg-f18-pet-imaging-and-how-to-avoid-them]

---

### Disclaimer & Data Validity:

The information provided in this document is for Research Use Only (RUO) and is strictly not intended for diagnostic or therapeutic procedures. While BenchChem strives to provide accurate protocols, we make no warranties, express or implied, regarding the fitness of this product for every specific experimental setup.

**Technical Support:** The protocols provided are for reference purposes. Unsure if this reagent suits your experiment? [[Contact our Ph.D. Support Team for a compatibility check](#)]

**Need Industrial/Bulk Grade?** [Request Custom Synthesis Quote](#)

## BenchChem

Our mission is to be the trusted global source of essential and advanced chemicals, empowering scientists and researchers to drive progress in science and industry.

### Contact

Address: 3281 E Guasti Rd  
Ontario, CA 91761, United States  
Phone: (601) 213-4426  
Email: [info@benchchem.com](mailto:info@benchchem.com)