

Technical Support Center: (R)-TISCH SPECT Imaging Artifacts

Author: BenchChem Technical Support Team. **Date:** December 2025

Compound of Interest

Compound Name: TISCH

Cat. No.: B1198486

[Get Quote](#)

Disclaimer: The term "(R)-**TISCH** SPECT" does not correspond to a standard clinical imaging agent in published literature. It is possible that this refers to a novel research compound. The following troubleshooting guide addresses common artifacts encountered in Single-Photon Emission Computed Tomography (SPECT) imaging, particularly in the context of cardiac studies, which are widely applicable. Researchers working with novel radiotracers should consider these common sources of error in addition to any unique properties of their specific agent.

Frequently Asked Questions (FAQs) & Troubleshooting Guides

This section provides answers to common questions regarding imaging artifacts and offers step-by-step guidance to identify and mitigate them.

Q1: What are the most common types of artifacts in SPECT imaging?

A1: Artifacts in SPECT imaging can be broadly categorized into three groups: patient-related, technical/instrumental, and processing-related issues.^{[1][2]}

- **Patient-Related Artifacts:** These are the most frequent and include patient motion, soft tissue attenuation (e.g., from breast tissue or the diaphragm), and uptake of the radiotracer in organs near the target area (e.g., liver, gut).^{[3][4][5][6]}

- **Technical/Instrumental Artifacts:** These arise from the SPECT camera system itself. Common examples include non-uniformity in the detector, errors in the center of rotation (COR), and misalignment of camera heads in multi-detector systems.[\[2\]](#)[\[3\]](#)[\[7\]](#)
- **Processing Artifacts:** These occur during the reconstruction of the SPECT images. They can be caused by incorrect filter selection, inappropriate axis selection, or misregistration between emission and transmission scans (in SPECT/CT).[\[1\]](#)[\[8\]](#)

Q2: My images show a perfusion defect in the inferior wall of the heart. How can I determine if this is a true defect or a soft tissue attenuation artifact?

A2: Inferior wall defects are commonly caused by attenuation from the diaphragm.[\[9\]](#) Here's how to troubleshoot this issue:

- **Review Raw Data:** Carefully inspect the rotating planar (cine) images. An attenuation artifact will typically show a consistent decrease in counts in the inferior wall across all angles, whereas a true defect may appear more localized.
- **Check for Normal Wall Motion:** In gated SPECT, normal thickening and motion of the inferior wall during the cardiac cycle suggest that the apparent defect is likely an artifact.[\[10\]](#)
- **Prone Imaging:** Re-imaging the patient in a prone position can help differentiate an attenuation artifact from a true defect. In the prone position, the heart moves away from the diaphragm, and if the defect resolves or is significantly reduced, it is likely an artifact.[\[3\]](#)
- **Attenuation Correction (AC):** If using a SPECT/CT system, applying CT-based attenuation correction should resolve the issue. If the defect persists after AC, it is more likely a true perfusion abnormality.[\[8\]](#)

Experimental Protocols

Protocol 1: Quality Control for SPECT Camera Uniformity

Objective: To ensure the gamma camera detector has a uniform response across its entire field of view, preventing "ring artifacts."

Methodology:

- **Source Preparation:** Use a liquid flood phantom filled with a uniform solution of a relevant radionuclide (e.g., ^{99m}Tc) or a solid ^{57}Co sheet source.
- **Acquisition:**
 - Remove the collimator.
 - Position the source at a distance of at least five times the useful field of view from the detector.
 - Acquire a high-count flood image (typically 30-100 million counts).
- **Analysis:**
 - Visually inspect the image for any non-uniformities (hot or cold spots).
 - Quantitatively analyze the image using the system's software to check that uniformity specifications are within the manufacturer's recommended limits.
- **Frequency:** This check should be performed daily before patient imaging.[\[7\]](#)

Data Presentation

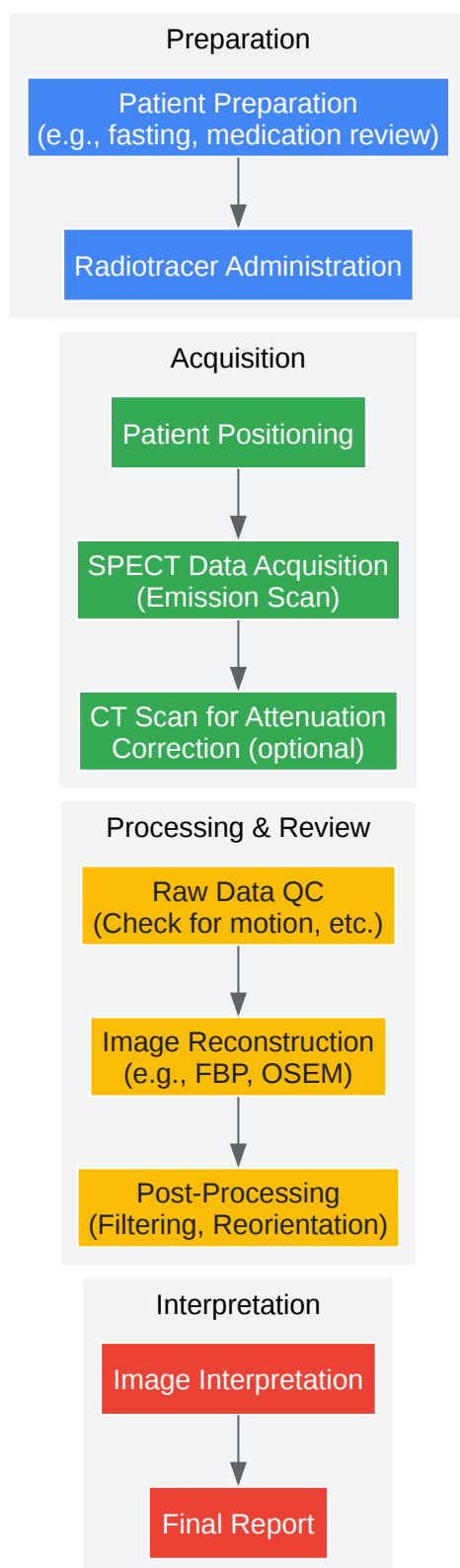
Table 1: Common SPECT Artifacts and Their Characteristics

Artifact Type	Common Cause	Appearance on Image	Troubleshooting Technique
Patient Motion	Patient movement during scan	Misalignment of projections, "hurricane sign" (opposing wall defects)[10]	Review cine data, motion correction software, re-acquire if severe[11]
Soft Tissue Attenuation	Photon absorption by breast, diaphragm, or body fat	Reduced counts in a specific region (e.g., anterior, inferior walls) [9]	Prone imaging, attenuation correction (SPECT/CT), ECG-gating analysis[3]
Center of Rotation (COR) Error	Misalignment of the detector's rotation axis	Blurring, loss of resolution, artifactual defects	Regular COR quality control checks[7]
Ring Artifact	Non-uniform detector response	Concentric rings in transaxial slices	Daily flood field uniformity checks[7]
Extracardiac Activity	High tracer uptake in liver, gallbladder, or gut	"Hot spots" near the heart that can obscure myocardial walls[2]	Encourage patient to drink water, eat a fatty meal (for some tracers), or delay imaging[2]

Visualizations

Diagram 1: General SPECT Imaging Workflow

A diagram illustrating the typical workflow for a SPECT imaging study, from patient preparation to final image analysis.

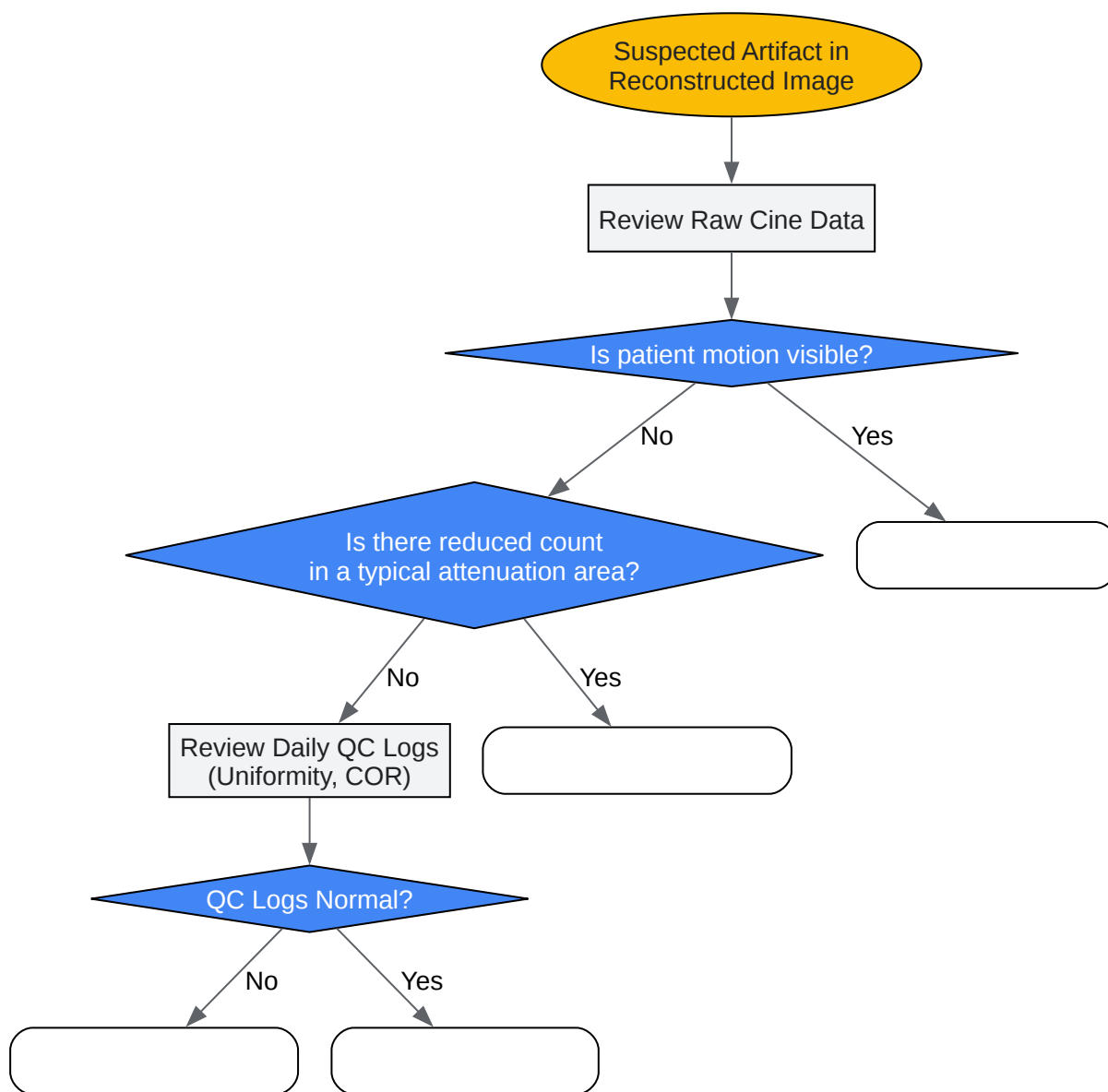


[Click to download full resolution via product page](#)

Caption: General workflow for a clinical SPECT imaging study.

Diagram 2: Troubleshooting Logic for Image Artifacts

A decision tree to guide users in identifying the source of a suspected artifact.



[Click to download full resolution via product page](#)

Caption: Decision tree for troubleshooting common SPECT artifacts.

Need Custom Synthesis?

BenchChem offers custom synthesis for rare earth carbides and specific isotopic labeling.

Email: info@benchchem.com or [Request Quote Online](#).

References

- 1. academic.oup.com [academic.oup.com]
- 2. revistamedicinamilitara.ro [revistamedicinamilitara.ro]
- 3. How to detect and avoid myocardial perfusion SPECT artifacts - PubMed [pubmed.ncbi.nlm.nih.gov]
- 4. Artifacts in nuclear cardiac imaging | PPTX [slideshare.net]
- 5. Nuclear Medicine Artifacts - StatPearls - NCBI Bookshelf [ncbi.nlm.nih.gov]
- 6. tech.snmjournals.org [tech.snmjournals.org]
- 7. jnm.snmjournals.org [jnm.snmjournals.org]
- 8. pubs.rsna.org [pubs.rsna.org]
- 9. UpToDate 2018 [sniv3r2.github.io]
- 10. static1.squarespace.com [static1.squarespace.com]
- 11. m.youtube.com [m.youtube.com]
- To cite this document: BenchChem. [Technical Support Center: (R)-TISCH SPECT Imaging Artifacts]. BenchChem, [2025]. [Online PDF]. Available at: [https://www.benchchem.com/product/b1198486#addressing-artifacts-in-r-tisch-spect-images]

Disclaimer & Data Validity:

The information provided in this document is for Research Use Only (RUO) and is strictly not intended for diagnostic or therapeutic procedures. While BenchChem strives to provide

accurate protocols, we make no warranties, express or implied, regarding the fitness of this product for every specific experimental setup.

Technical Support: The protocols provided are for reference purposes. Unsure if this reagent suits your experiment? [[Contact our Ph.D. Support Team for a compatibility check](#)]

Need Industrial/Bulk Grade? [Request Custom Synthesis Quote](#)

BenchChem

Our mission is to be the trusted global source of essential and advanced chemicals, empowering scientists and researchers to drive progress in science and industry.

Contact

Address: 3281 E Guasti Rd
Ontario, CA 91761, United States
Phone: (601) 213-4426
Email: info@benchchem.com