

Application Notes and Protocols for Non-Invasive Imaging in Hepatomegaly Monitoring

Author: BenchChem Technical Support Team. **Date:** December 2025

Compound of Interest

Compound Name: GSD-1

Cat. No.: B1192801

[Get Quote](#)

For Researchers, Scientists, and Drug Development Professionals

Introduction

Hepatomegaly, or an enlarged liver, is a significant clinical finding that can indicate underlying hepatic diseases such as non-alcoholic fatty liver disease (NAFLD), alcoholic liver disease, viral hepatitis, or malignancy.[1][2] Monitoring changes in liver size and volume is crucial for diagnosing these conditions, assessing disease progression, and evaluating the efficacy of therapeutic interventions in preclinical and clinical research. Non-invasive imaging techniques offer a powerful alternative to invasive liver biopsies, providing quantitative and qualitative data on liver morphology and pathology without the associated risks and sampling errors.[3][4] This document provides detailed application notes and protocols for the use of key non-invasive imaging modalities in the monitoring of hepatomegaly.

Imaging Modalities for Hepatomegaly Assessment

Several non-invasive imaging techniques are routinely employed to assess liver size and volume. The choice of modality often depends on the specific research question, required accuracy, and available resources. The primary modalities include Ultrasound, Computed Tomography (CT), Magnetic Resonance Imaging (MRI), and Transient Elastography.[3][5]

Data Summary: Quantitative Comparison of Imaging Modalities

The following table summarizes the key quantitative aspects of different non-invasive imaging techniques for the assessment of liver size and related pathologies.

Imaging Modality	Key Quantitative Metrics	Sensitivity	Specificity	Advantages	Limitations
Ultrasound (US)	Craniocaudal length (mid-clavicular line), Liver span, Parenchymal echogenicity	For moderate/severe steatosis: 80-89% [6]	For moderate/severe steatosis: 87-90% [6]	Widely available, low cost, real-time imaging, no ionizing radiation. [7]	Operator dependent, limited in obese patients, lower sensitivity for mild steatosis. [6] [7]
Computed Tomography (CT)	Liver volume (volumetry), Liver attenuation (Hounsfield Units)	For hepatomegaly (craniocaudal threshold of 19 cm): 71% [8]	For hepatomegaly (craniocaudal threshold of 19 cm): 86% [8]	Fast acquisition, high spatial resolution, accurate volume assessment. [9]	Ionizing radiation exposure, potential for contrast agent toxicity. [10]
Magnetic Resonance Imaging (MRI)	Liver volume (volumetry), Proton Density Fat Fraction (PDFF)	High for liver volume and fat quantification.	High for liver volume and fat quantification.	Excellent soft tissue contrast, no ionizing radiation, accurate quantification of fat and iron. [10]	High cost, longer acquisition times, contraindications (e.g., pacemakers). [10]
Transient Elastography (FibroScan®)	Liver Stiffness Measurement (kPa), Controlled	For significant fibrosis: High	For significant fibrosis: High	Rapid, non-invasive assessment of liver stiffness	Can be influenced by obesity, ascites, and acute

Attenuation
Parameter
(CAP) (dB/m)

(fibrosis) and inflammation.
steatosis. [\[11\]](#)

Experimental Protocols

Ultrasound Protocol for Hepatomegaly Assessment

Objective: To obtain standardized measurements of liver size and assess parenchymal echotexture.

Materials:

- Ultrasound system with a curvilinear transducer (2-5 MHz).[\[5\]](#)
- Acoustic coupling gel.

Procedure:

- Patient Preparation: The patient should fast for 4-6 hours to reduce bowel gas and ensure gallbladder distention.
- Patient Positioning: The patient is positioned supine with their right arm raised above their head to expand the intercostal spaces.
- Transducer Placement and Imaging:
 - Apply coupling gel to the right upper quadrant of the abdomen.
 - Place the transducer in the mid-clavicular line, just below the costal margin.
 - Obtain a longitudinal (sagittal) view of the right lobe of the liver.
 - Measure the craniocaudal (CC) length from the dome of the diaphragm to the inferior tip of the right lobe. A measurement greater than 15.5-16 cm is generally considered indicative of hepatomegaly.[\[1\]](#)

- Sweep through the entire liver in both sagittal and transverse planes to assess the overall size, contour, and parenchymal echogenicity.[12]
- Document any focal lesions or abnormalities.
- Assess the echogenicity of the liver parenchyma relative to the right kidney cortex. Increased echogenicity can be indicative of steatosis.

Computed Tomography (CT) Protocol for Liver Volumetry

Objective: To accurately measure the total liver volume.

Materials:

- Multidetector CT (MDCT) scanner.
- Intravenous (IV) non-ionic iodinated contrast medium (if required for other indications).
- Automated injector pump.

Procedure:

- Patient Preparation: The patient may be required to fast for 4 hours prior to the scan.
- Patient Positioning: The patient is positioned supine on the CT table with their arms raised above their head.[13]
- Scanning Parameters:
 - Scout Image: Anteroposterior and lateral scout images are obtained to plan the scan range.
 - Scan Extent: From the dome of the diaphragm to the iliac crest.
 - Scan Phase: For volumetry, a non-contrast or portal venous phase scan is typically sufficient. The portal venous phase is acquired approximately 60-70 seconds after the initiation of IV contrast injection.[13]

- Collimation and Slice Thickness: Use thin collimation (e.g., 0.625-1.25 mm) to acquire isotropic data, which allows for high-quality multiplanar reformations. Reconstruct axial images with a slice thickness of 2.5-5 mm.
- Post-processing and Volumetry:
 - The acquired axial images are transferred to a post-processing workstation.
 - Specialized software is used to manually or semi-automatically trace the contour of the liver on each axial slice, excluding the gallbladder, major blood vessels, and fissures.[9]
 - The software then calculates the total liver volume by summing the areas of the traced regions and multiplying by the slice thickness.

Magnetic Resonance Imaging (MRI) Protocol for Liver Volumetry and Fat Quantification

Objective: To obtain precise liver volume measurements and quantify the percentage of fat in the liver parenchyma.

Materials:

- 1.5T or 3T MRI scanner.
- Abdominal phased-array coil.
- IV gadolinium-based contrast agent (optional, depending on the specific protocol).

Procedure:

- Patient Preparation: The patient should fast for 4-6 hours prior to the scan.
- Patient Positioning: The patient is positioned supine on the MRI table with the abdominal coil centered over the liver.
- Imaging Sequences: A typical liver MRI protocol includes:

- T1-weighted in-phase and out-of-phase gradient-echo sequences: These are essential for the qualitative and quantitative assessment of hepatic steatosis. A signal drop on the out-of-phase images compared to the in-phase images indicates the presence of microscopic fat.[\[14\]](#)
- T2-weighted sequences (e.g., HASTE, fat-suppressed T2-weighted turbo spin-echo): These sequences are used to assess for fluid, inflammation, and focal lesions.[\[14\]](#)
- 3D T1-weighted gradient-echo sequence (e.g., VIBE, LAVA): Acquired before and after contrast administration (if used) for dynamic assessment and high-resolution anatomical detail. These sequences are also used for liver volumetry.[\[15\]](#)[\[16\]](#)
- Proton Density Fat Fraction (PDFF) sequences: Specialized multi-echo gradient-echo sequences are used to accurately quantify the percentage of fat in the liver.
- Post-processing for Volumetry and Fat Quantification:
 - Volumetry: Similar to CT, the 3D T1-weighted images are loaded into a post-processing software. The liver contours are traced on each slice to calculate the total volume.[\[15\]](#)
 - Fat Quantification: PDFF maps are automatically generated by the MRI software, providing a pixel-by-pixel measurement of the fat fraction. Regions of interest (ROIs) are drawn on the PDFF map to obtain an average fat fraction for the entire liver or specific segments.

Transient Elastography (FibroScan®) Protocol

Objective: To measure liver stiffness (an indicator of fibrosis) and the controlled attenuation parameter (CAP), which correlates with hepatic steatosis.

Materials:

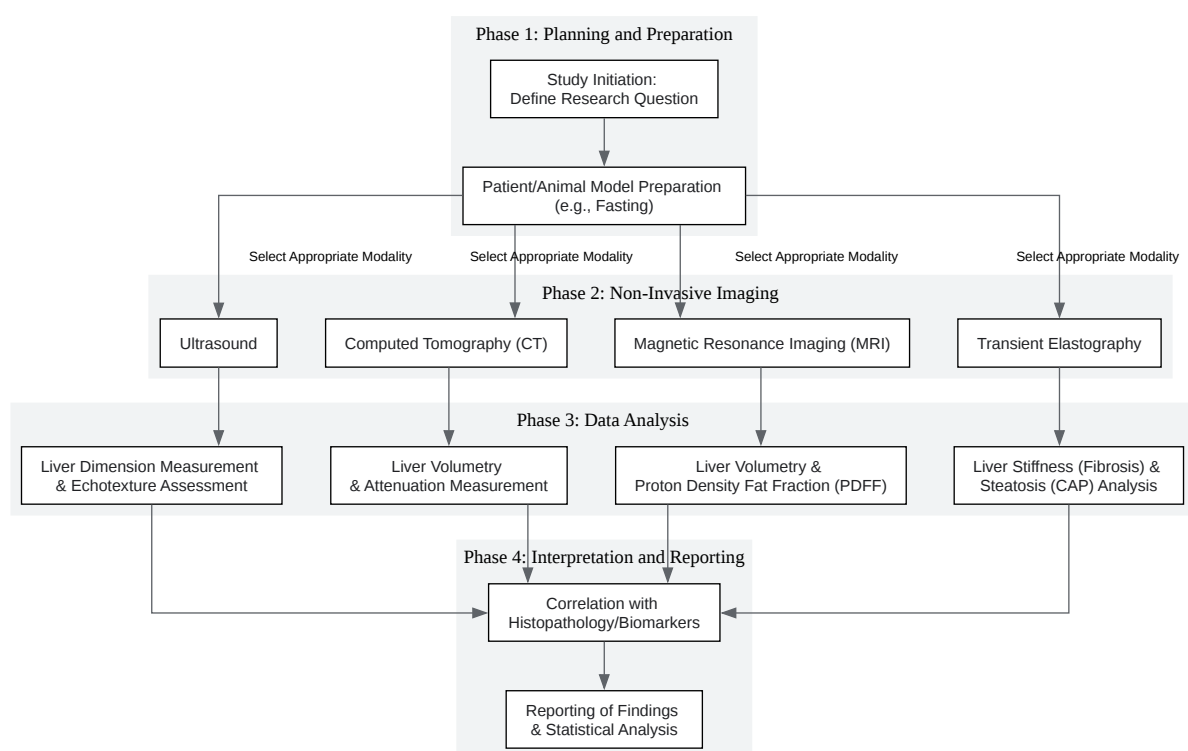
- FibroScan® device with a standard (M) or large (XL) probe, depending on the patient's body habitus.

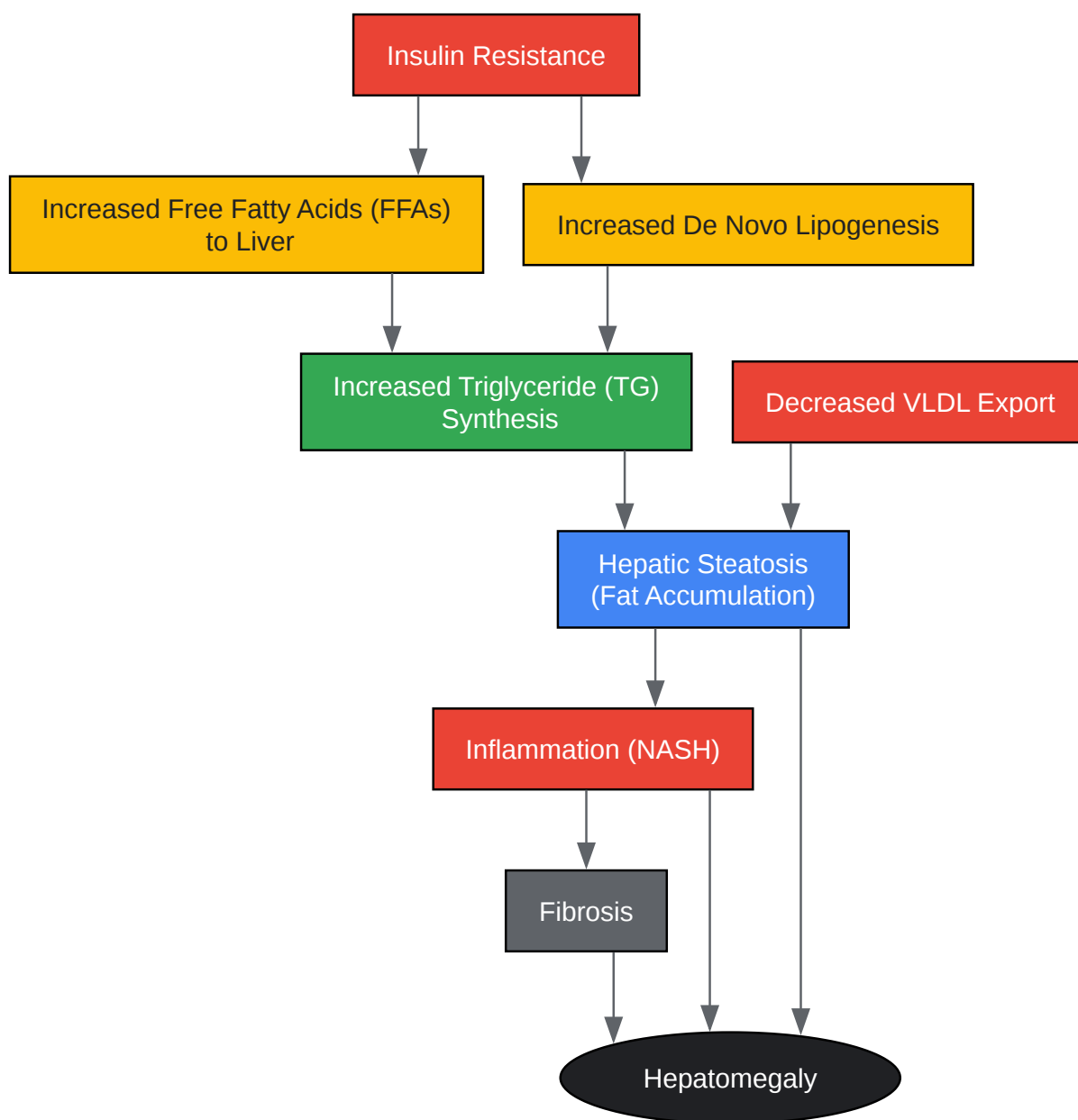
Procedure:

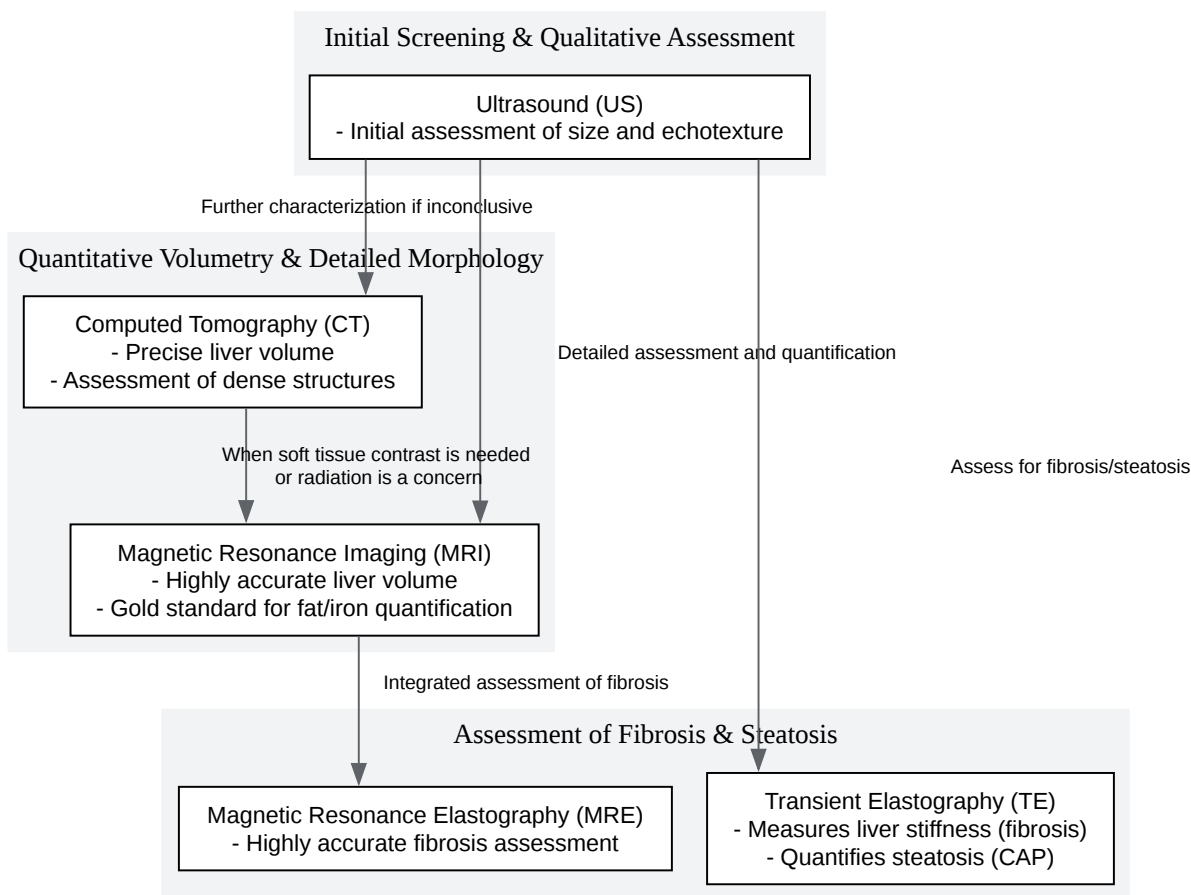
- Patient Preparation: The patient should fast for at least 3 hours.

- Patient Positioning: The patient lies in the supine position with their right arm in maximal abduction.
 - Probe Placement: The probe is placed in an intercostal space in the right mid-axillary line, over the area of the right lobe of the liver.
 - Measurement Acquisition:
 - The operator applies the probe to the skin with slight pressure.
 - A button is pressed to initiate a measurement. A low-frequency elastic shear wave is propagated through the liver tissue.
 - The velocity of the shear wave is measured by ultrasound and is directly related to the stiffness of the liver.
 - The device software simultaneously calculates the CAP value.
 - The operator obtains at least 10 valid measurements. The median liver stiffness value (in kilopascals, kPa) and the median CAP value (in decibels per meter, dB/m) are reported.
- [17]

Visualizations







[Click to download full resolution via product page](#)

Need Custom Synthesis?

BenchChem offers custom synthesis for rare earth carbides and specific isotopic labeling.

Email: info@benchchem.com or [Request Quote Online](#).

References

- 1. radiopaedia.org [radiopaedia.org]
- 2. Fatty liver disease - Wikipedia [en.wikipedia.org]
- 3. Noninvasive imaging of hepatic dysfunction: A state-of-the-art review - PMC [pmc.ncbi.nlm.nih.gov]
- 4. Non invasive tools for the diagnosis of liver cirrhosis - PMC [pmc.ncbi.nlm.nih.gov]
- 5. researchgate.net [researchgate.net]
- 6. Liver fat imaging—a clinical overview of ultrasound, CT, and MR imaging - PMC [pmc.ncbi.nlm.nih.gov]
- 7. Liver Imaging - StatPearls - NCBI Bookshelf [ncbi.nlm.nih.gov]
- 8. pubs.rsna.org [pubs.rsna.org]
- 9. jcdr.net [jcdr.net]
- 10. researchgate.net [researchgate.net]
- 11. youtube.com [youtube.com]
- 12. google.com [google.com]
- 13. radiopaedia.org [radiopaedia.org]
- 14. radiopaedia.org [radiopaedia.org]
- 15. Computerized Liver Volumetry on MRI by Using 3D Geodesic Active Contour Segmentation - PMC [pmc.ncbi.nlm.nih.gov]
- 16. mrimaster.com [mrimaster.com]
- 17. youtube.com [youtube.com]
- To cite this document: BenchChem. [Application Notes and Protocols for Non-Invasive Imaging in Hepatomegaly Monitoring]. BenchChem, [2025]. [Online PDF]. Available at: [https://www.benchchem.com/product/b1192801#non-invasive-imaging-techniques-for-monitoring-hepatomegaly]

Disclaimer & Data Validity:

The information provided in this document is for Research Use Only (RUO) and is strictly not intended for diagnostic or therapeutic procedures. While BenchChem strives to provide accurate protocols, we make no warranties, express or implied, regarding the fitness of this product for every specific experimental setup.

Technical Support: The protocols provided are for reference purposes. Unsure if this reagent suits your experiment? [[Contact our Ph.D. Support Team for a compatibility check](#)]

Need Industrial/Bulk Grade? [Request Custom Synthesis Quote](#)

BenchChem

Our mission is to be the trusted global source of essential and advanced chemicals, empowering scientists and researchers to drive progress in science and industry.

Contact

Address: 3281 E Guasti Rd

Ontario, CA 91761, United States

Phone: (601) 213-4426

Email: info@benchchem.com