

Application of Fundus Autofluorescence in Ophthalmology: Detailed Application Notes and Protocols

Author: BenchChem Technical Support Team. **Date:** December 2025

Compound of Interest

Compound Name: *bilifuscin*

Cat. No.: *B1171575*

[Get Quote](#)

For Researchers, Scientists, and Drug Development Professionals

Introduction

Fundus autofluorescence (FAF) is a non-invasive imaging modality that provides a metabolic map of the retina, offering insights into the health and function of the retinal pigment epithelium (RPE).[1][2] Unlike fluorescein angiography, FAF does not require the injection of a dye, as it utilizes the natural fluorescence of endogenous fluorophores within the retina. The primary source of this fluorescence is lipofuscin, a metabolic byproduct that accumulates in the RPE cells over time and in various disease states.[1][2] FAF imaging has become an invaluable tool in the diagnosis, monitoring of progression, and evaluation of therapeutic response in a wide range of retinal diseases.[3][4] This document provides detailed application notes and protocols for the use of FAF in ophthalmology research and drug development.

Principle of Fundus Autofluorescence

FAF imaging is based on the principle of fluorescence, where a molecule absorbs light at a specific wavelength and emits light at a longer wavelength. In the eye, the dominant fluorophore is lipofuscin, which accumulates in the lysosomes of RPE cells as a byproduct of the phagocytosis of photoreceptor outer segments.[5] The major fluorescent component of lipofuscin is a bisretinoid compound called A2E.[5]

FAF imaging systems typically use a blue or green excitation light to stimulate the lipofuscin in the RPE. The emitted fluorescent light, usually in the yellow-orange spectrum, is then captured by a detector to create a two-dimensional map of the fundus.[6]

Key FAF Signal Interpretations:

- **Hyperautofluorescence (Increased Signal):** Indicates excessive lipofuscin accumulation, which can be a sign of RPE stress or dysfunction.[1] This is often observed in the junctional zones around areas of geographic atrophy in age-related macular degeneration (AMD) and in certain retinal dystrophies.[7]
- **Hypoautofluorescence (Decreased Signal):** Represents a loss or absence of lipofuscin, which can be due to RPE cell death, as seen in geographic atrophy, or the presence of material blocking the fluorescent signal, such as blood or pigment.[1]

Clinical Applications

FAF is a valuable tool for a variety of retinal conditions:

- **Age-Related Macular Degeneration (AMD):** FAF is crucial for identifying and monitoring the progression of geographic atrophy (GA), the advanced form of dry AMD.[8] Different FAF patterns at the junction of GA have been shown to predict the rate of atrophy progression.[9]
- **Inherited Retinal Diseases:** FAF is instrumental in diagnosing and managing inherited retinal diseases such as Stargardt disease, Best disease, and retinitis pigmentosa (RP).[3] In RP, a characteristic hyperautofluorescent ring is often observed, which constricts over time as the disease progresses.[3][10]
- **Drug Toxicity:** FAF can detect early signs of retinal toxicity from certain medications, such as hydroxychloroquine, often before changes are visible with other imaging modalities.[5]
- **White Dot Syndromes and Inflammatory Conditions:** FAF helps in the diagnosis and monitoring of inflammatory conditions affecting the outer retina and RPE.[3]

Quantitative Data Presentation

Quantitative fundus autofluorescence (qAF) is an advanced technique that allows for the measurement of FAF intensity levels, providing a more objective assessment of lipofuscin content.^[11] This is achieved by calibrating the FAF image to an internal reference of known fluorescence.^[12]

Table 1: Normative Quantitative Autofluorescence (qAF8) Values in Healthy Eyes

Age Group (Years)	Mean qAF8 (qAF units)	Key Observations
5-18	Low, with a steady increase	QAF increases with maturation. ^[13]
20-60	Significant increase with age	qAF levels increase with age. ^{[4][7][14]}
>60	Continued increase, may level off after 70	

Note: qAF values can be influenced by factors such as ethnicity and sex, with females and White individuals tending to have higher values.^{[4][7][14]}

Table 2: Quantitative Autofluorescence (qAF8) in Age-Related Macular Degeneration (AMD)

AMD Stage	Mean qAF8 (qAF units)	Key Observations
Early AMD	Decreased compared to age-matched controls	qAF levels decline early in the disease process. ^[15]
Intermediate AMD	Significantly decreased compared to controls	
Geographic Atrophy (GA)	Lowest mean qAF values	Indicates significant RPE cell loss. ^[5]
Subretinal Drusenoid Deposits (SDD)	Significantly lower than controls	

Table 3: Quantitative Autofluorescence (qAF) in Retinitis Pigmentosa (RP)

Retinal Location	qAF Measurement	Key Observations
Within Hyper-AF Ring	Can be higher, similar, or lower than healthy controls	In a significant percentage of cases (28-47%), qAF over the ring is higher than in healthy eyes, suggesting increased fluorophore production. [1] [14] [16]
Internal to Hyper-AF Ring	Often within the normal range for healthy eyes in a majority of patients (71%)	
External to Hyper-AF Ring	Can be within, above, or below the normal range for healthy eyes	

Table 4: Geographic Atrophy (GA) Progression Rates Measured by FAF

Study	Mean/Median GA Growth Rate (mm ² /year)
Holmen et al. (2019)	0.97 (Mean) [9]
Holz et al.	1.52 (Median)
Sunness et al. (using CFP)	2.1 (Median)
FAME Study	1.49 (Median) [15]

Experimental Protocols

Protocol 1: Fundus Autofluorescence Image Acquisition (using confocal Scanning Laser Ophthalmoscope - cSLO)

1. Patient Preparation:

- Obtain informed consent.

- Dilate the patient's pupils to at least 6mm using 0.5% tropicamide and 2.5% phenylephrine to ensure an uninterrupted light path.[8][17]
- Position the patient comfortably at the cSLO device, with their chin on the chinrest and forehead against the forehead rest.[8][17]

2. Image Acquisition Setup:

- Select the FAF imaging mode on the cSLO software.
- For standard FAF, use an excitation wavelength of 488 nm (blue light) and a barrier filter to detect emissions above 500 nm.[11]
- For near-infrared FAF (NIR-FAF), use an excitation wavelength of 787 nm and a barrier filter for emissions above 800 nm.[6]
- Set the field of view, typically 30° x 30° or 55° x 55°.

3. Image Capture:

- Align the camera to the patient's pupil and focus on the retina.
- Instruct the patient to fixate on the internal fixation target.
- Acquire a series of images. Many systems use an automatic real-time (ART) mode to average multiple frames (e.g., 9-16 frames) to improve the signal-to-noise ratio.[18]
- Ensure the image is evenly illuminated and free of artifacts from the cornea, lens, or eyelashes.

Protocol 2: Quantitative Fundus Autofluorescence (qAF) Analysis

1. Image Acquisition for qAF:

- Follow the FAF image acquisition protocol (Protocol 1).
- Crucially, the cSLO must be equipped with a certified internal fluorescent reference.[12] This reference is imaged simultaneously with the retina.

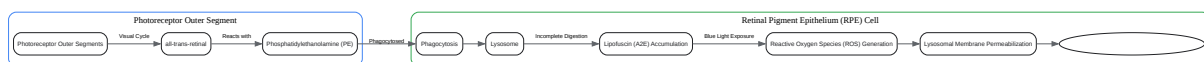2. Image Processing and Analysis (using ImageJ/Fiji or similar software):

- Image Import: Open the raw FAF image file in the analysis software.[16][18]
- Calibration:
- Measure the mean gray level (GL) of the internal reference in a predefined region of interest (ROI).[11]

- Use the known fluorescence of the internal reference to calibrate the pixel gray levels of the entire image to qAF units.[11]
- Region of Interest (ROI) Selection:
- Define standardized ROIs for analysis. A common method is to use a grid of concentric rings and segments centered on the fovea (e.g., the Delori grid).[11]
- For specific pathologies, manually draw ROIs around the area of interest (e.g., the hyperautofluorescent ring in RP or areas of GA).[1]
- Data Extraction:
- Measure the mean qAF value within each defined ROI.
- Exclude retinal blood vessels from the analysis as they are hypoautofluorescent and can skew the results.
- Corrections: Apply corrections for factors that can influence the qAF signal, such as the patient's age, lens density, and pupil size, using established formulas if available.[11]
- Data Analysis: Compare the measured qAF values to normative data or track changes over time for longitudinal studies.

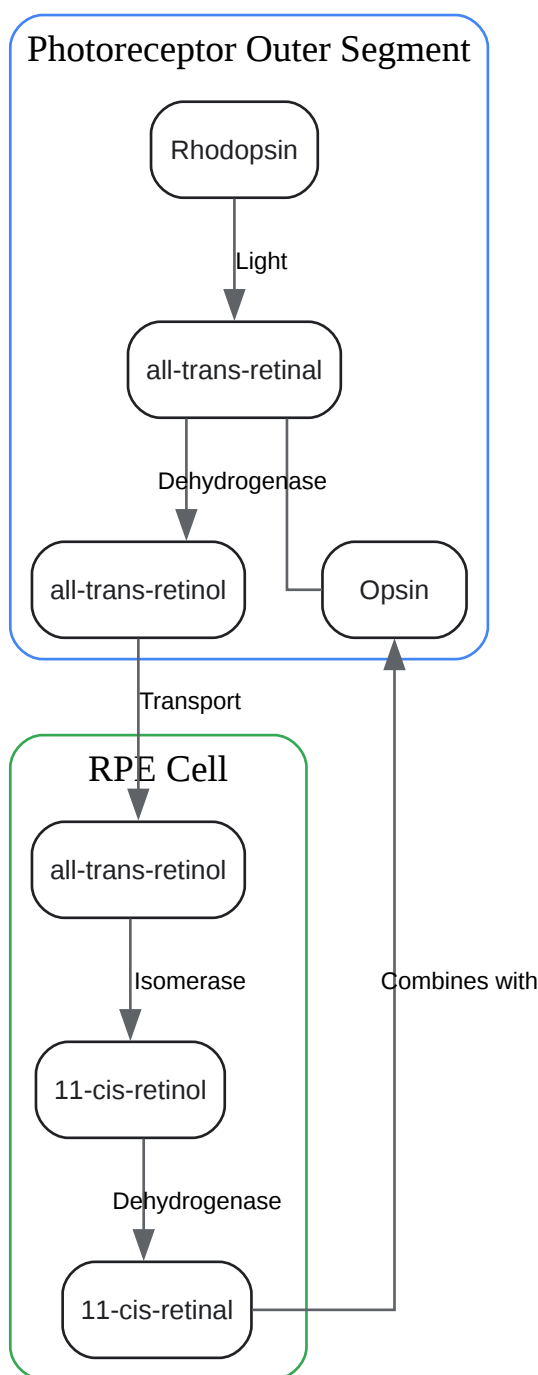
Visualizations

Signaling Pathways and Experimental Workflows



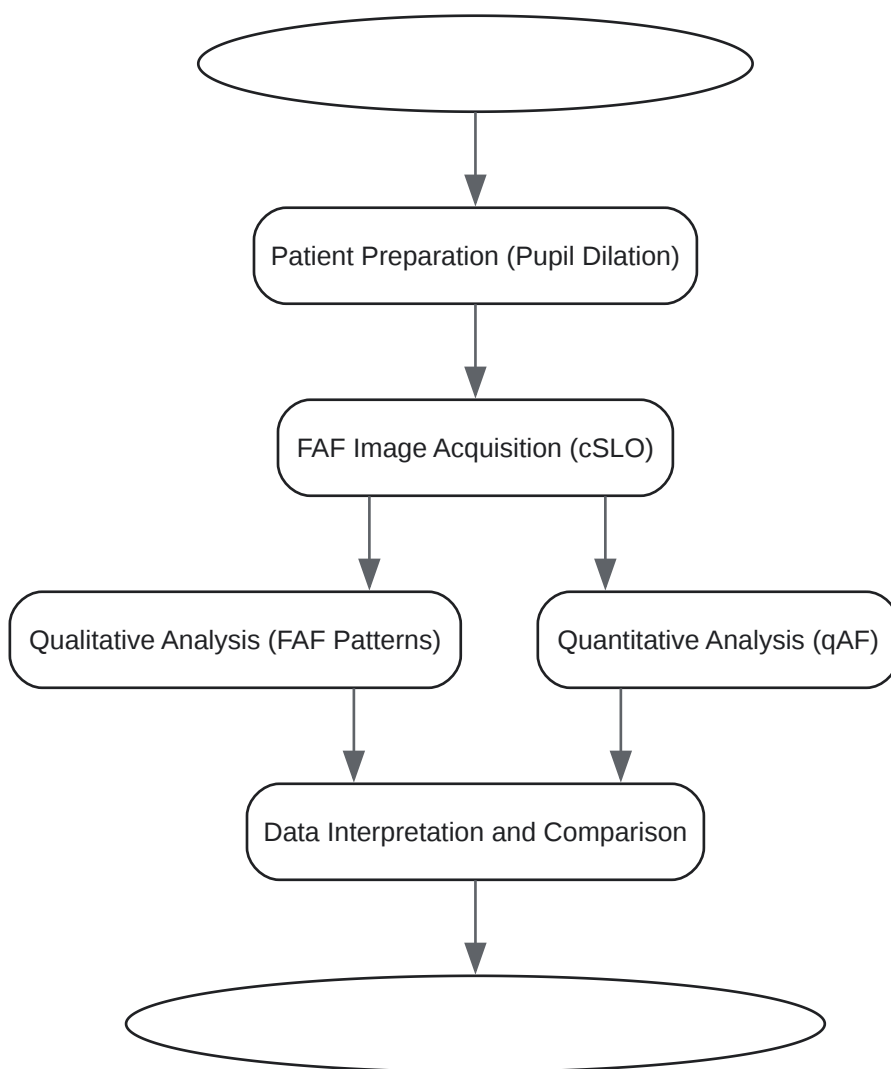
[Click to download full resolution via product page](#)

Caption: Lipofuscin accumulation pathway leading to RPE cell death.



[Click to download full resolution via product page](#)

Caption: The visual cycle pathway in the retina.



[Click to download full resolution via product page](#)

Caption: Experimental workflow for Fundus Autofluorescence imaging.

Need Custom Synthesis?

BenchChem offers custom synthesis for rare earth carbides and specific isotopic labeling.

Email: info@benchchem.com or [Request Quote Online](#).

References

- 1. researchgate.net [researchgate.net]

- 2. Formation of lipofuscin-like material in the RPE Cell by different components of rod outer segments - PMC [pmc.ncbi.nlm.nih.gov]
- 3. Quantifying Fundus Autofluorescence in Patients With Retinitis Pigmentosa - PMC [pmc.ncbi.nlm.nih.gov]
- 4. Visual Pathway - Ophthalmology - Eye | PPTX [slideshare.net]
- 5. Deep Learning to Predict the Future Growth of Geographic Atrophy from Fundus Autofluorescence - PMC [pmc.ncbi.nlm.nih.gov]
- 6. researchgate.net [researchgate.net]
- 7. scholarsarchive.byu.edu [scholarsarchive.byu.edu]
- 8. Insightful Imaging for Geographic Atrophy | Retinal Physician [retinalphysician.com]
- 9. FAF Imaging and Progression of Geographic Atrophy in AMD - American Academy of Ophthalmology [aao.org]
- 10. m.youtube.com [m.youtube.com]
- 11. Neuroanatomy, Visual Pathway - StatPearls - NCBI Bookshelf [ncbi.nlm.nih.gov]
- 12. researchgate.net [researchgate.net]
- 13. [PDF] Quantitative Fundus Autofluorescence: Advanced Analysis Tools | Semantic Scholar [semanticscholar.org]
- 14. iovs.arvojournals.org [iovs.arvojournals.org]
- 15. Use of Fundus Autofluorescence Images to Predict Geographic Atrophy Progression - PMC [pmc.ncbi.nlm.nih.gov]
- 16. Quantitative Fundus Autofluorescence: Advanced Analysis Tools - PMC [pmc.ncbi.nlm.nih.gov]
- 17. youtube.com [youtube.com]
- 18. A Workflow to Quantitatively Determine Age-Related Macular Degeneration Lesion-Specific Variations in Fundus Autofluorescence [jove.com]
- To cite this document: BenchChem. [Application of Fundus Autofluorescence in Ophthalmology: Detailed Application Notes and Protocols]. BenchChem, [2025]. [Online PDF]. Available at: [https://www.benchchem.com/product/b1171575#application-of-fundus-autofluorescence-in-ophthalmology]

Disclaimer & Data Validity:

The information provided in this document is for Research Use Only (RUO) and is strictly not intended for diagnostic or therapeutic procedures. While BenchChem strives to provide accurate protocols, we make no warranties, express or implied, regarding the fitness of this product for every specific experimental setup.

Technical Support: The protocols provided are for reference purposes. Unsure if this reagent suits your experiment? [[Contact our Ph.D. Support Team for a compatibility check](#)]

Need Industrial/Bulk Grade? [Request Custom Synthesis Quote](#)

BenchChem

Our mission is to be the trusted global source of essential and advanced chemicals, empowering scientists and researchers to drive progress in science and industry.

Contact

Address: 3281 E Guasti Rd
Ontario, CA 91761, United States
Phone: (601) 213-4426
Email: info@benchchem.com