

techniques to minimize redetachment after MIRAgel removal

Author: BenchChem Technical Support Team. **Date:** December 2025

Compound of Interest

Compound Name: *Miragel*

Cat. No.: *B1168782*

[Get Quote](#)

Technical Support Center: MIRAgel Removal

This technical support center provides guidance for researchers, scientists, and drug development professionals on techniques to minimize retinal redetachment following the removal of **MIRAgel** scleral buckles.

Troubleshooting Guides

This section addresses specific issues that may be encountered during **MIRAgel** removal surgery.

Issue 1: Friable **MIRAgel** buckle leading to fragmentation during removal.

- Question: My team is experiencing frequent fragmentation of the **MIRAgel** implant during explantation, leaving behind residual particles. How can we ensure complete removal and minimize inflammation?
- Answer: The friability of degraded **MIRAgel** is a well-documented challenge.[1] To mitigate this, consider a suction-assisted removal technique. This approach can help capture small fragments as the buckle is manipulated.
 - Recommended Technique: Utilize a Yankauer suction catheter with a diameter adjusted to the surgical space.[2] Gentle aspiration of the degraded hydrogel can facilitate its removal in a more controlled manner, reducing the likelihood of leaving behind inflammatory

remnants.[3][4] Meticulous irrigation and inspection of the surgical field for any residual translucent fragments are crucial before closure.

Issue 2: Significant scleral thinning or ectasia is observed intraoperatively.

- Question: We have identified severe scleral ectasia under the **MIRAgel** implant. What is the best approach to remove the buckle without causing a globe perforation, and how should the thinned sclera be managed to prevent future complications?
- Answer: Severe scleral thinning is a serious complication of long-term **MIRAgel** implantation and significantly increases the risk of intraoperative scleral perforation.[5][6]
 - Surgical Approach: Extreme care must be taken during dissection of the capsule overlying the buckle. Avoid sharp dissection directly on the sclera. If the buckle is adherent to the thinned sclera, consider a piecemeal removal technique, carefully separating the implant from the scleral bed. In cases of extreme thinning, leaving a thin layer of the inner capsule adherent to the sclera may be preferable to aggressive scraping that could lead to perforation.
 - Management of Scleral Thinning: If a perforation occurs or the sclera is deemed unstable, a scleral patch graft (e.g., donor sclera, pericardium, or Tutoplast) should be available and used to reinforce the area.[7][8] This provides structural support and reduces the risk of postoperative staphyloma formation.

Issue 3: The **MIRAgel** buckle has intruded into the vitreous cavity.

- Question: Preoperative imaging and intraoperative findings confirm that a portion of the **MIRAgel** buckle has eroded through the sclera and is now in the vitreous cavity. What is the recommended surgical strategy to address this?
- Answer: Intraocular intrusion of a **MIRAgel** buckle requires a combined external and internal approach, typically involving pars plana vitrectomy (PPV).[6][9]
 - Recommended Protocol:
 - Perform a standard three-port pars plana vitrectomy to gain access to the intravitreal portion of the **MIRAgel**.[10]

- Externally, dissect and remove the episcleral portion of the buckle as completely as possible.
- Internally, use an ultrasonic fragmatome to break up and aspirate the intravitreal **MIRAgel** fragments.[2][11][12] This allows for controlled removal of the implant material while minimizing traction on the retina.[9]
- Thoroughly inspect the peripheral retina for any new or missed retinal breaks, paying close attention to the area of intrusion.
- Address any retinal breaks with endolaser photocoagulation or cryotherapy.[13]
- A tamponade agent (gas or silicone oil) may be necessary depending on the extent of retinal pathology.[14]
- Repair the scleral defect with a patch graft.[7]

Frequently Asked Questions (FAQs)

Q1: What is the expected rate of retinal redetachment after **MIRAgel** removal?

A1: The rate of retinal redetachment after **MIRAgel** removal is a significant concern.[2][6] One large case series reported that intraoperative scleral perforation or retinal redetachment occurred in 11% of cases undergoing **MIRAgel** explantation.[5] Studies on the removal of scleral buckles in general (not specific to **MIRAgel**) have shown redetachment rates around 10%.[15] The risk may be higher for encircling buckles compared to segmental ones.[12]

Q2: Should prophylactic laser retinopexy be performed at the time of **MIRAgel** removal to reduce the risk of redetachment?

A2: The role of prophylactic laser retinopexy at the time of scleral buckle removal is not definitively established. Some studies have investigated this, finding low overall rates of redetachment after buckle removal regardless of whether prophylactic laser was applied.[1][5] One study showed a redetachment rate of 2.2% in the group that received laser versus 4.6% in the group that did not, a difference that was not statistically significant.[1][5] The decision to perform prophylactic laser should be made on a case-by-case basis, considering the preoperative retinal status and any intraoperative findings.

Q3: What are the key elements of postoperative care to minimize the risk of redetachment?

A3: While there are no protocols specifically for **MIRAgel** removal, the principles of postoperative care after general scleral buckle surgery are applicable.

- Medications: A course of topical antibiotics to prevent infection and corticosteroids to control inflammation is standard.[4][16]
- Activity Restrictions: Patients should be advised to avoid strenuous activities, heavy lifting, and bending at the waist for a period recommended by the surgeon, typically a few weeks.[7][17]
- Monitoring: Close follow-up is essential to monitor for signs of redetachment, such as an increase in floaters, new photopsias, or a visual field defect.[4][11] The early postoperative period is critical, as most redetachments after buckle removal occur within the first few months.

Q4: What are the known risk factors for retinal redetachment after scleral buckle removal?

A4: While data specific to **MIRAgel** removal is limited, general risk factors for redetachment after vitreoretinal surgery are likely relevant. These include a history of previous failed retinal surgeries, high myopia, and the presence of proliferative vitreoretinopathy (PVR).[14][18][19][20] In the context of buckle removal, the removal of an encircling band may carry a higher risk than the removal of a segmental buckle.[12]

Data Presentation

Table 1: Reported Rates of Retinal Redetachment After Scleral Buckle Removal

Study Cohort	Number of Eyes	Redetachment Rate	Notes	Citation(s)
MIRAgel Removal	467	11% (combined rate of intraoperative scleral perforation or redetachment)	Large case series specifically on MIRAgel explantation.	[5]
General Scleral Buckle Removal	40	10.0%	Retrospective study of various buckle types.	[15]
General Scleral Buckle Removal (Encircling vs. Segmental)	40	25.0% (Encircling) vs. 0.0% (Segmental)	Sub-analysis showing higher risk with encircling buckle removal.	[12]
General Scleral Buckle Removal with/without Prophylactic Laser	87	3.4% (Overall)	2.2% with laser vs. 4.2% without laser (not statistically significant).	[1]

Experimental Protocols

Protocol 1: Suction-Assisted **MIRAgel** Removal

- **Anesthesia and Exposure:** Administer appropriate anesthesia (general or retrobulbar). Perform a conjunctival peritomy to expose the encapsulated **MIRAgel** buckle.
- **Capsule Incision:** Carefully incise the fibrous capsule overlying the implant. Avoid deep cuts to prevent damage to the underlying thinned sclera.
- **Suture Removal:** Identify and cut any non-absorbable scleral sutures securing the implant.
- **Implant Aspiration:**

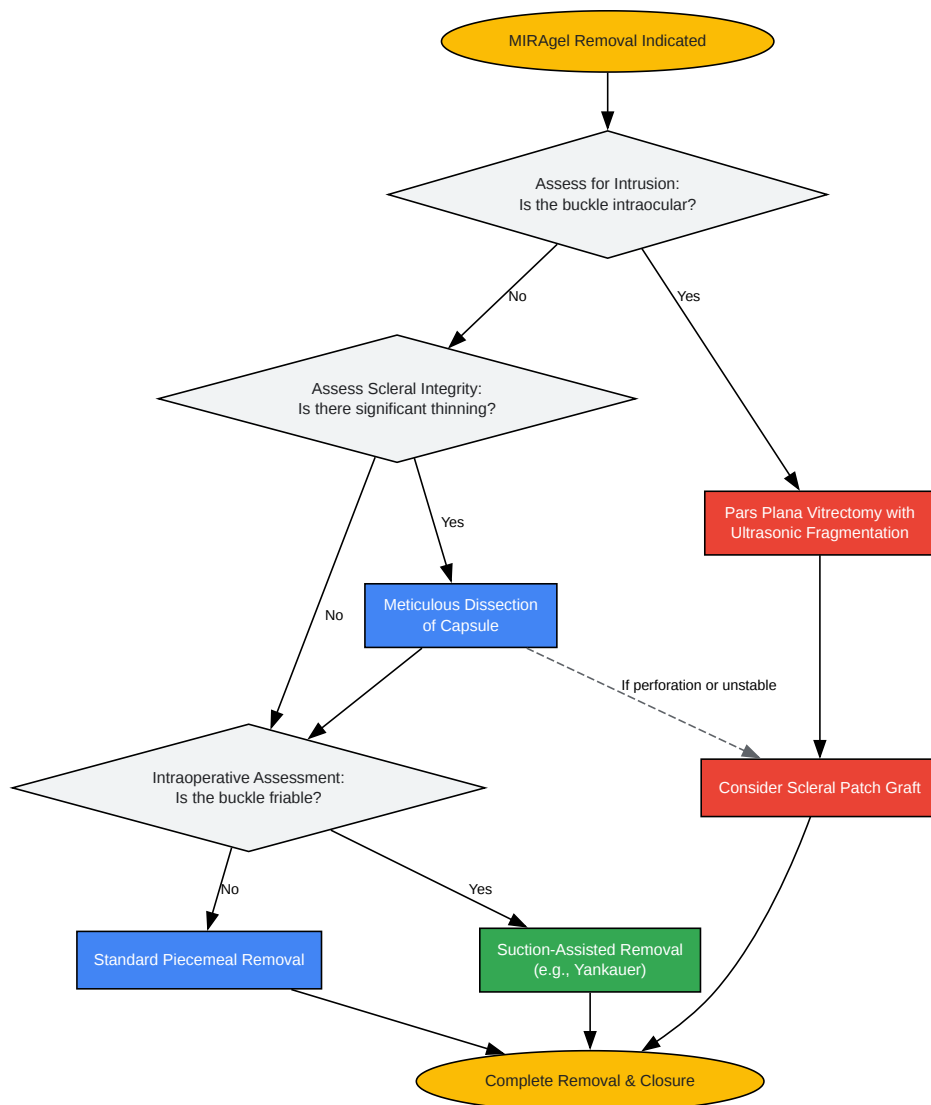
- Introduce a Yankauer suction catheter, with its diameter potentially trimmed to fit the surgical space, into the capsular pocket.[\[2\]](#)[\[3\]](#)
- Apply gentle, controlled suction to aspirate the friable, degraded **MIRAgel** material.
- Use a blunt instrument, such as a muscle hook, to gently manipulate the remaining implant towards the suction tip.
- Complete Removal and Inspection: Meticulously explore the entire length of the buckle's former location to ensure no fragments remain. The friable nature of **MIRAgel** necessitates a thorough search.[\[4\]](#)
- Irrigation: Irrigate the surgical field with a balanced salt solution.
- Closure: Close the Tenon's capsule and conjunctiva in layers.[\[16\]](#)

Protocol 2: Management of Intruded **MIRAgel** with Pars Plana Vitrectomy

- Combined Approach: This procedure involves both an external approach to the episcleral portion of the buckle and an internal vitrectomy approach.
- External Dissection: As in Protocol 1, expose and remove the external components of the **MIRAgel** buckle.
- Pars Plana Vitrectomy (PPV):
 - Perform a standard three-port 23- or 25-gauge PPV.[\[14\]](#)
 - Induce a posterior vitreous detachment if not already present.
 - Remove the central and peripheral vitreous.
- Intraocular Implant Removal:
 - Introduce a pars plana ultrasonic fragmatome.[\[2\]](#)[\[11\]](#)[\[12\]](#)
 - Carefully fragment and aspirate the intravitreal portion of the **MIRAgel** buckle.[\[9\]](#) Shave the intruded material down to the level of the retina.

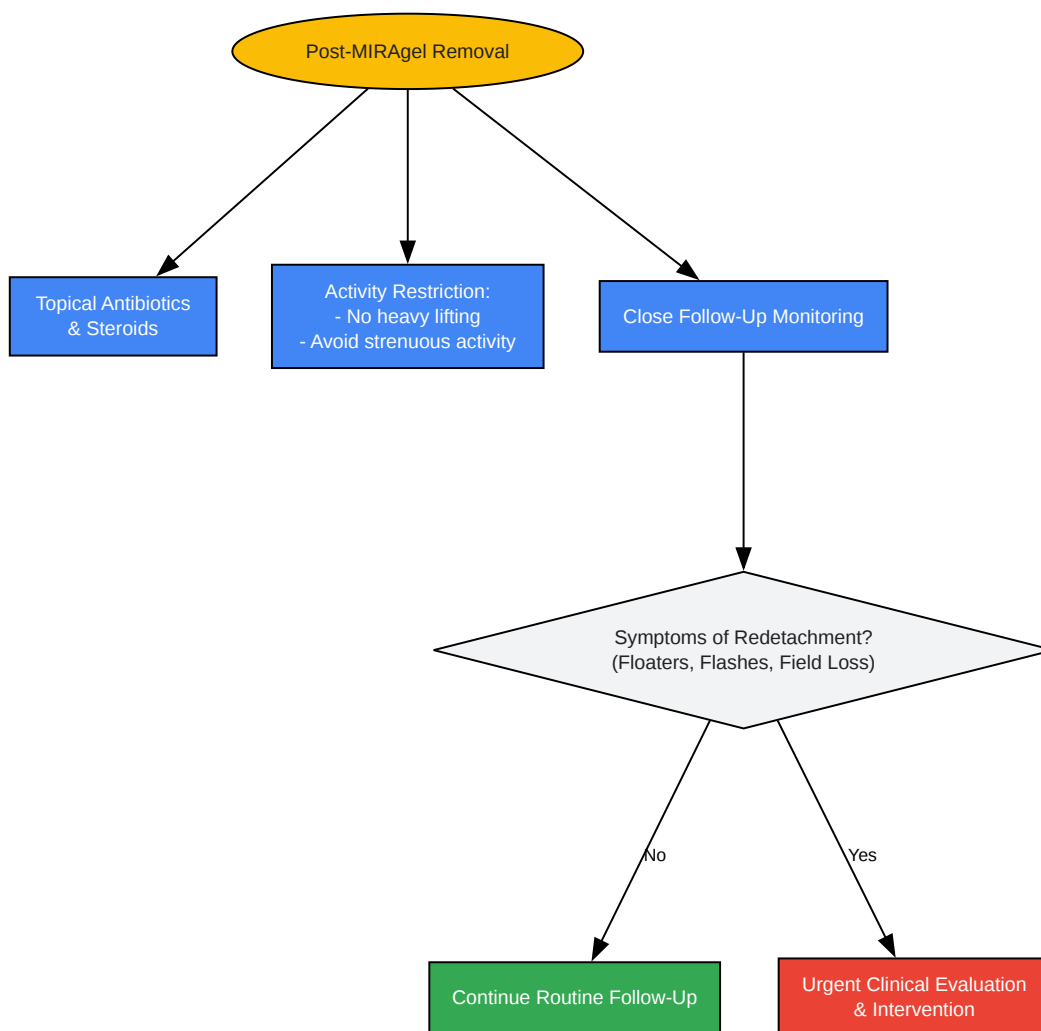
- Retinal Inspection and Treatment:
 - Perform a thorough 360-degree scleral depressed examination of the peripheral retina to identify any retinal breaks, paying special attention to the intrusion site.
 - Treat any identified breaks with endolaser photocoagulation or cryotherapy.
- Scleral Defect Repair: Repair the scleral entry site of the intruded buckle with a scleral patch graft.^[7]
- Tamponade and Closure: Based on the stability of the retina, decide on the use of a tamponade agent (e.g., SF₆, C₃F₈ gas, or silicone oil).^[14] Close the sclerotomies and conjunctiva.

Visualizations



[Click to download full resolution via product page](#)

Caption: Surgical decision workflow for **MIRAgel** removal.



[Click to download full resolution via product page](#)

Caption: Postoperative management pathway after **MIRAgel** removal.

Need Custom Synthesis?

BenchChem offers custom synthesis for rare earth carbides and specific isotopic labeling.

Email: info@benchchem.com or [Request Quote Online](#).

References

- 1. Outcomes of scleral buckle removal with and without concurrent prophylactic laser retinopexy - PubMed [pubmed.ncbi.nlm.nih.gov]
- 2. Complications Associated with MIRAgel for Treatment of Retinal Detachment - PubMed [pubmed.ncbi.nlm.nih.gov]
- 3. iovs.arvojournals.org [iovs.arvojournals.org]
- 4. drugs.com [drugs.com]
- 5. iovs.arvojournals.org [iovs.arvojournals.org]
- 6. researchgate.net [researchgate.net]
- 7. nycretna.com [nycretna.com]
- 8. Scleral thinning causes, diagnosis, and management: A narrative review - PubMed [pubmed.ncbi.nlm.nih.gov]
- 9. researchgate.net [researchgate.net]
- 10. Vitrectomy - Patients - The American Society of Retina Specialists [asrs.org]
- 11. my.clevelandclinic.org [my.clevelandclinic.org]
- 12. Management of complex retinal detachment from intraocular invasion of MIRAgel-a case report - PubMed [pubmed.ncbi.nlm.nih.gov]
- 13. vrcny.com [vrcny.com]
- 14. Retinal redetachment after silicone oil removal: a risk factor analysis - PMC [pmc.ncbi.nlm.nih.gov]
- 15. PROPHYLACTIC LASER RETINOPEXY AND SCLERAL BUCKLE PLACEMENT FOR RETINAL DETACHMENT PREVENTION IN PIERSON SYNDROME: A Retrospective, Case Series Study - PubMed [pubmed.ncbi.nlm.nih.gov]
- 16. researchgate.net [researchgate.net]
- 17. assets.ctfassets.net [assets.ctfassets.net]

- 18. Retinal redetachment after silicone oil removal in proliferative vitreoretinopathy: a prognostic factor analysis - PubMed [pubmed.ncbi.nlm.nih.gov]
- 19. Risk factors for redetachment and worse visual outcome after silicone oil removal in eyes with complicated retinal detachment - PubMed [pubmed.ncbi.nlm.nih.gov]
- 20. Risk Factors for Retinal Redetachment After Silicone Oil Removal: A Systematic Review and Meta-Analysis - PubMed [pubmed.ncbi.nlm.nih.gov]
- To cite this document: BenchChem. [techniques to minimize redetachment after MIRAgel removal]. BenchChem, [2025]. [Online PDF]. Available at: [https://www.benchchem.com/product/b1168782#techniques-to-minimize-redetachment-after-miragel-removal]

Disclaimer & Data Validity:

The information provided in this document is for Research Use Only (RUO) and is strictly not intended for diagnostic or therapeutic procedures. While BenchChem strives to provide accurate protocols, we make no warranties, express or implied, regarding the fitness of this product for every specific experimental setup.

Technical Support: The protocols provided are for reference purposes. Unsure if this reagent suits your experiment? [[Contact our Ph.D. Support Team for a compatibility check](#)]

Need Industrial/Bulk Grade? [Request Custom Synthesis Quote](#)

BenchChem

Our mission is to be the trusted global source of essential and advanced chemicals, empowering scientists and researchers to drive progress in science and industry.

Contact

Address: 3281 E Guasti Rd
Ontario, CA 91761, United States
Phone: (601) 213-4426
Email: info@benchchem.com