

comparing imaging findings of MIRAgel to orbital tumors

Author: BenchChem Technical Support Team. **Date:** December 2025

Compound of Interest

Compound Name: *Miragel*

Cat. No.: *B1168782*

[Get Quote](#)

A Comparative Guide to the Imaging Findings of **MIRAgel** and Orbital Tumors for Researchers and Drug Development Professionals

In the realm of orbital imaging, the differentiation between benign post-surgical changes and neoplastic processes is of paramount importance for accurate diagnosis and subsequent management. **MIRAgel**, a hydrogel formerly used in scleral buckling procedures for retinal detachment, can undergo long-term hydrolysis and expansion, creating a mass-like lesion that can mimic an orbital tumor on imaging. This guide provides a detailed comparison of the imaging findings of hydrolyzed **MIRAgel** and common orbital tumors, supported by experimental data and protocols to aid researchers, scientists, and drug development professionals in this diagnostic challenge.

Data Presentation: Comparative Imaging Characteristics

The following tables summarize the key imaging features of hydrolyzed **MIRAgel** and common orbital tumors on Computed Tomography (CT) and Magnetic Resonance Imaging (MRI).

Table 1: CT Imaging Findings

Feature	Hydrolyzed MIRAgel Scleral Buckle	Orbital Lymphoma	Orbital Cavernous Hemangioma	Orbital Metastases
Morphology	Circumferential or localized mass-like structure conforming to the globe.[1][2][3]	Homogeneous, well-circumscribed, or infiltrative mass that molds to adjacent structures.[4][5]	Well-circumscribed, ovoid or round, intraconal mass.[6][7]	Often irregular and infiltrative, but can be a discrete mass.[8][9]
Attenuation	Intermediate attenuation between fluid and soft tissue.	Typically isodense to slightly hyperdense compared to extraocular muscles.[5]	Iso- to slightly hyperdense to muscle.	Variable, can be isodense, hypodense, or hyperdense.
Enhancement	Peripheral rim enhancement of the surrounding fibrous capsule is common.[1]	Mild to moderate homogeneous enhancement.[4][5][10]	Progressive, centripetal enhancement ("filling-in") is characteristic.[6][11]	Variable, often heterogeneous or rim-enhancing.[9]
Calcification	Dystrophic calcifications within the mass or along the rim are a key feature.[1][12]	Rare.	Phleboliths (calcifications) can be present.	Uncommon, but can be seen in metastases from certain primary tumors (e.g., breast, prostate).
Bone Involvement	Generally conforms to the globe without bone destruction, though erosion has been	Typically no bone destruction; the tumor molds to the orbital bones.[4][5]	May cause smooth bone remodeling or expansion.	Bony destruction is a common feature.[8]

reported in rare
cases.[\[3\]](#)

Table 2: MRI Imaging Findings

Feature	Hydrolyzed MIRAgel Scleral Buckle	Orbital Lymphoma	Orbital Cavernous Hemangioma	Orbital Metastases
T1-weighted Signal	Isointense to extraocular muscle.[1][2]	Isointense to extraocular muscle.[4][10][13]	Isointense to extraocular muscle.[6][11]	Generally hypointense to fat.[9]
T2-weighted Signal	Markedly hyperintense (fluid-like signal). [1][2]	Isointense to hyperintense relative to muscle; can be hypointense in high-grade lymphomas.[4][5]	Markedly and homogeneously hyperintense.[6][11][14]	Often hyperintense to fat.[9]
T1 C+ (Gadolinium)	Peripheral rim enhancement of the capsule.[1]	Mild to moderate homogeneous enhancement.[4][10]	Progressive and centripetal enhancement.[6][11][14]	Variable, often avid and heterogeneous enhancement.[9]
Diffusion (DWI/ADC)	No specific ADC values reported in the literature. Expected to show high ADC values due to high water content.	Restricted diffusion with low ADC values is characteristic, especially in high-grade lymphomas.[5]	No significant restricted diffusion; variable ADC values have been reported. [14]	Can show restricted diffusion with low ADC values, but this is variable.
Key Differentiating Features	History of scleral buckle, circumferential shape, dystrophic calcifications.[1][12][15]	Molds to structures without bone destruction, restricted diffusion.[4][5]	Well-circumscribed intraconal location, progressive centripetal enhancement.[6][11][14]	History of primary malignancy, bone destruction, often irregular and infiltrative.[8]

Experimental Protocols: Recommended Imaging Protocol

A standardized, multi-parametric imaging protocol is crucial for the differentiation of a suspected hydrolyzed **MIRAgel** buckle from an orbital tumor. The following is a recommended protocol based on best practices for orbital imaging.

MRI of the Orbits Protocol

- Patient Preparation: No specific preparation is required. A thorough clinical history, specifically inquiring about prior ophthalmic surgeries, is critical.
- Coil: Head coil or a dedicated orbit surface coil for higher resolution.
- Sequences:
 - T1-weighted (T1W) Axial and Coronal: Provides excellent anatomical detail of the orbital structures.
 - Repetition Time (TR): 400-600 ms
 - Echo Time (TE): 10-20 ms
 - Slice Thickness: 2-3 mm
 - T2-weighted (T2W) Axial and Coronal with Fat Suppression: Crucial for detecting edema and characterizing fluid content. Fat suppression enhances the visibility of lesions within the orbital fat.
 - TR: 3000-4000 ms
 - TE: 80-100 ms
 - Slice Thickness: 2-3 mm
 - Short Tau Inversion Recovery (STIR) Coronal: Provides uniform fat suppression and is sensitive to fluid.

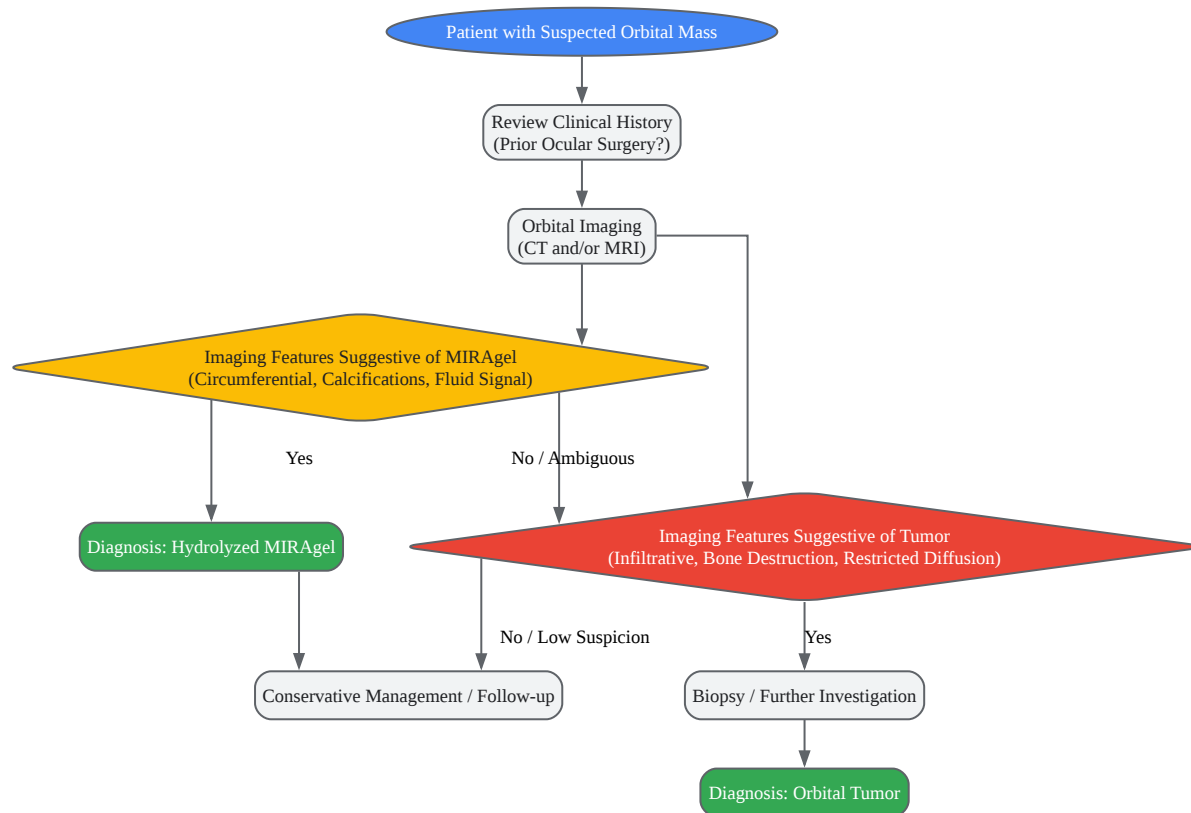
- TR: 4000-5000 ms
- TE: 50-70 ms
- Inversion Time (TI): 140-160 ms
- Slice Thickness: 2-3 mm
- Diffusion-Weighted Imaging (DWI) Axial: Essential for assessing tissue cellularity.
 - b-values: 0, 500, 1000 s/mm²
 - ADC maps should be generated.
- T1-weighted (T1W) Axial and Coronal with Fat Suppression post-Gadolinium contrast: To evaluate the enhancement pattern of the lesion. Dynamic contrast-enhanced (DCE) MRI can be particularly useful to observe the pattern of contrast uptake over time, which is characteristic for cavernous hemangiomas.[16]

CT of the Orbits Protocol

- Patient Preparation: No specific preparation is required unless intravenous contrast is planned.
- Technique:
 - Non-contrast Axial and Coronal thin-slice (1-2mm) acquisition: To assess for calcifications and bony involvement.
 - Contrast-enhanced Axial and Coronal thin-slice (1-2mm) acquisition: To evaluate the enhancement pattern.

Mandatory Visualization

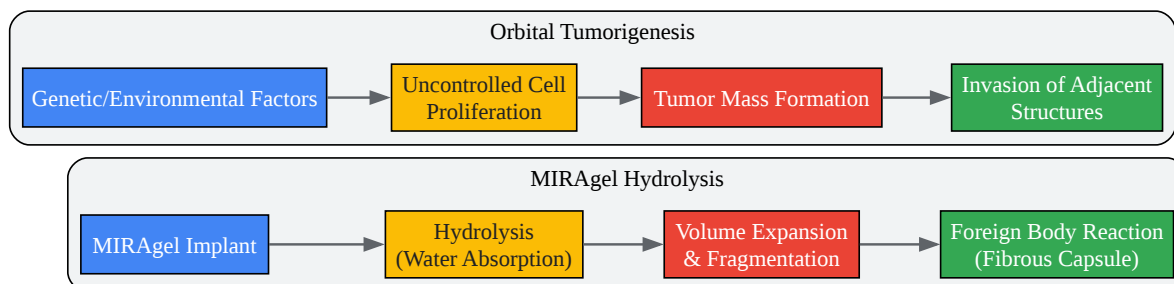
Diagram 1: Diagnostic Workflow for a Suspected Orbital Mass



[Click to download full resolution via product page](#)

A diagnostic workflow for evaluating a patient with a suspected orbital mass.

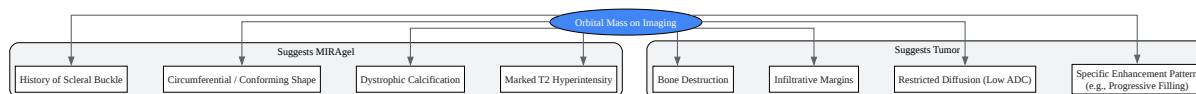
Diagram 2: Comparative Signaling Pathways (Hypothetical Pathophysiology)



[Click to download full resolution via product page](#)

A simplified comparison of the hypothetical pathophysiological pathways.

Diagram 3: Key Imaging Differentiators



[Click to download full resolution via product page](#)

Key imaging features that help differentiate between **MIRAgel** and orbital tumors.

Need Custom Synthesis?

BenchChem offers custom synthesis for rare earth carbides and specific isotopic labeling.

Email: info@benchchem.com or [Request Quote Online](#).

References

- 1. Imaging of Hydrogel Episcleral Buckle Fragmentation as a Late Complication After Retinal Reattachment Surgery - PMC [pmc.ncbi.nlm.nih.gov]
- 2. kindai.repo.nii.ac.jp [kindai.repo.nii.ac.jp]
- 3. Hydrogel (Miragel®) scleral explant, late orbital complication - PMC [pmc.ncbi.nlm.nih.gov]
- 4. Orbital lymphoma: imaging features and differential diagnosis - PMC [pmc.ncbi.nlm.nih.gov]
- 5. aao.org [aao.org]
- 6. Diagnostic Imaging Methods and Comparative Analysis of Orbital Cavernous Hemangioma - PMC [pmc.ncbi.nlm.nih.gov]
- 7. researchgate.net [researchgate.net]
- 8. radiopaedia.org [radiopaedia.org]
- 9. brieflands.com [brieflands.com]
- 10. scispace.com [scispace.com]
- 11. Orbital cavernous hemangiomas: ultrasound and magnetic resonance imaging evaluation - PubMed [pubmed.ncbi.nlm.nih.gov]
- 12. Multimodality imaging of hydrogel scleral buckles - PubMed [pubmed.ncbi.nlm.nih.gov]
- 13. To Explore MR Imaging Radiomics for the Differentiation of Orbital Lymphoma and IgG4-Related Ophthalmic Disease - PMC [pmc.ncbi.nlm.nih.gov]
- 14. researchgate.net [researchgate.net]
- 15. Clinical and radiographic features of hydrolyzed MIRAgel scleral buckles: A comparative analysis - PubMed [pubmed.ncbi.nlm.nih.gov]
- 16. Advances in magnetic resonance imaging of orbital disease - PMC [pmc.ncbi.nlm.nih.gov]
- To cite this document: BenchChem. [comparing imaging findings of MIRAgel to orbital tumors]. BenchChem, [2025]. [Online PDF]. Available at: [https://www.benchchem.com/product/b1168782#comparing-imaging-findings-of-miragel-to-orbital-tumors]

Disclaimer & Data Validity:

The information provided in this document is for Research Use Only (RUO) and is strictly not intended for diagnostic or therapeutic procedures. While BenchChem strives to provide accurate protocols, we make no warranties, express or implied, regarding the fitness of this product for every specific experimental setup.

Technical Support: The protocols provided are for reference purposes. Unsure if this reagent suits your experiment? [[Contact our Ph.D. Support Team for a compatibility check](#)]

Need Industrial/Bulk Grade? [Request Custom Synthesis Quote](#)

BenchChem

Our mission is to be the trusted global source of essential and advanced chemicals, empowering scientists and researchers to drive progress in science and industry.

Contact

Address: 3281 E Guasti Rd

Ontario, CA 91761, United States

Phone: (601) 213-4426

Email: info@benchchem.com