

Technical Support Center: Diagnosing MIRAgel Buckle-Related Orbital Pseudotumor

Author: BenchChem Technical Support Team. **Date:** December 2025

Compound of Interest

Compound Name: *Miragel*

Cat. No.: *B1168782*

[Get Quote](#)

This technical support center provides troubleshooting guides and frequently asked questions (FAQs) for researchers, scientists, and drug development professionals investigating **MIRAgel** buckle-related orbital pseudotumor.

Troubleshooting Guides

Issue: Patient Presents with Orbital Mass and a Vague History of Eye Surgery

Question: How can we confirm if a patient's orbital symptoms are related to a past **MIRAgel** scleral buckle surgery, especially when their recollection of the specific implant used is unclear?

Answer:

A multi-step approach is crucial when a patient's surgical history is ambiguous.

- Detailed Clinical History: While the patient may not recall the term "**MIRAgel**," inquire about retinal detachment surgery performed between the 1980s and mid-1990s.^[1] Symptoms often appear many years, even decades, after the initial surgery.^{[1][2]} Key symptoms to ask about include progressive proptosis, diplopia (double vision), a palpable mass, pain or discomfort, and restricted eye movements.^{[1][3][2]}

- **Thorough Clinical Examination:** Look for signs such as a palpable orbital mass, proptosis (bulging of the eye), restricted extraocular motility, and conjunctival swelling or redness.[3][4]
- **Orbital Imaging:** This is the most critical step for diagnosis. Both Computed Tomography (CT) and Magnetic Resonance Imaging (MRI) are highly valuable.
 - CT scans may reveal a circumferential soft tissue mass surrounding the globe, sometimes with calcifications.[3] The expanded hydrogel can appear as a cystic or heterogeneous mass.[2][5]
 - MRI scans can further characterize the lesion. The appearance can vary, but it often shows a mass with specific signal characteristics.[6]
- **Review of Old Medical Records:** If possible, obtaining original surgical records is the most definitive way to confirm the type of scleral buckle used.

Issue: Imaging Results are Atypical and Suggest a Malignant Tumor

Question: The orbital imaging of our subject shows a mass with features concerning for a primary orbital tumor. How can we differentiate this from a **MIRAgel** buckle-related pseudotumor before proceeding with an aggressive biopsy?

Answer:

The ability of a hydrolyzed **MIRAgel** buckle to mimic an orbital neoplasm is a significant diagnostic challenge.[6][7] Here's how to approach this:

- **Re-evaluate Patient History:** A history of retinal detachment surgery, even decades prior, is a major red flag for a **MIRAgel**-related complication.[2][5] The absence of a known primary cancer elsewhere in the body also lowers the suspicion of a metastatic orbital tumor.
- **Specific Imaging Clues:** While it can mimic a tumor, a swollen **MIRAgel** buckle has some characteristic radiographic features. It often appears as a circumferential or horseshoe-shaped lesion in the extraconal space, conforming to the globe's curvature.[4][8] On CT, it may present as a lobulated, heterogeneous soft tissue mass.[5] On MRI, the signal can be

variable, but it may appear as a low-signal intensity lesion on T2-weighted images due to fibrosis.[9][10]

- Consider the Differential Diagnosis: The primary differential diagnoses include orbital lymphoma, idiopathic orbital inflammatory pseudotumor, and metastatic tumors.[11] A key feature of **MIRAgel** complications is their direct association with the location of the previous scleral buckle.
- Proton Magnetic Resonance Spectroscopy (MRS): In some cases, MRS can help differentiate the composition of the mass and rule out suppurative or neoplastic processes.[1]
- Surgical Exploration and Excisional Biopsy: If the diagnosis remains uncertain, surgical exploration is warranted. The characteristic appearance of crumbly, whitish, gelatinous fragments of the **MIRAgel** material upon surgical exploration is often diagnostic.[5] An excisional biopsy, rather than an incisional one, is often preferred to both confirm the diagnosis and provide treatment.

Frequently Asked Questions (FAQs)

Q1: What is a **MIRAgel** scleral buckle and why does it cause orbital pseudotumor?

A1: **MIRAgel** is a hydrogel material that was used for scleral buckles in retinal detachment surgery, primarily in the 1980s and early 1990s.[1][3] Over time, the material undergoes hydrolytic degradation, causing it to absorb water and expand significantly, sometimes to several times its original size.[1][2] This expansion and fragmentation can lead to a chronic foreign body granulomatous inflammatory reaction, presenting as an orbital pseudotumor.[5][12]

Q2: What are the typical long-term complications associated with **MIRAgel** buckles?

A2: Long-term complications are primarily due to the hydrolysis and expansion of the implant. These include:

- Pain and discomfort[1][2]
- A palpable mass under the eyelid or conjunctiva[1][2]

- Diplopia (double vision) and restricted eye movements[1][2]
- Proptosis (bulging of the eye)[4]
- Inflammation mimicking orbital cellulitis[13][14]
- Scleral erosion and, in rare cases, intrusion into the globe[1][2]

Q3: What is the typical timeframe for the onset of symptoms?

A3: Symptoms of **MIRAgel** buckle complications are typically delayed, often presenting 10 to 30 years after the initial surgery.[1][6]

Q4: Is surgical removal of the **MIRAgel** buckle always necessary?

A4: In symptomatic patients, surgical removal of the expanded and fragmented **MIRAgel** material is the definitive treatment.[1][13] Conservative management may be considered in asymptomatic patients where the finding is incidental, but close monitoring is advised.

Q5: What are the challenges associated with the surgical removal of a **MIRAgel** buckle?

A5: Surgical removal can be challenging due to the friable nature of the hydrolyzed material, which can break into small pieces, making complete removal difficult.[1] There is also a risk of scleral thinning or necrosis under the buckle, which can increase the risk of scleral perforation during removal.[2][8]

Data Presentation

Table 1: Comparison of Clinical and Radiological Features

Feature	MIRAgel Buckle-Related Pseudotumor	Idiopathic Orbital Inflammatory Pseudotumor (IOIP)	Orbital Lymphoma
Patient History	History of retinal detachment surgery (1980s-1990s)	Often no relevant surgical history; may have autoimmune conditions	May have a history of lymphoma elsewhere
Onset	Insidious, progressive over months to years	Acute to subacute, often with pain	Insidious, slowly progressive
Pain	Variable, can be painless or associated with discomfort	Often a prominent feature, especially in the acute phase	Typically painless
CT Findings	Circumferential or lobulated mass conforming to the globe, possible calcifications	Diffuse infiltration of orbital fat, enlargement of extraocular muscles (including tendons), ill-defined margins	Well-defined, homogenous mass that molds to orbital structures
MRI T1 Signal	Isointense to muscle	Isointense to muscle	Isointense to muscle
MRI T2 Signal	Often hypointense (low signal) due to fibrosis	Variable, can be hyperintense or hypointense	Isointense to slightly hyperintense
Contrast Enhancement	Rim enhancement is common	Diffuse, moderate to marked enhancement	Moderate, homogenous enhancement
Location	Extraconal, following the path of the scleral buckle	Can involve any part of the orbit (myositic, dacryoadenitis, diffuse)	Often involves the lacrimal gland or superior orbit

Experimental Protocols

Histopathological Examination of Excised MIRAgel Fragments

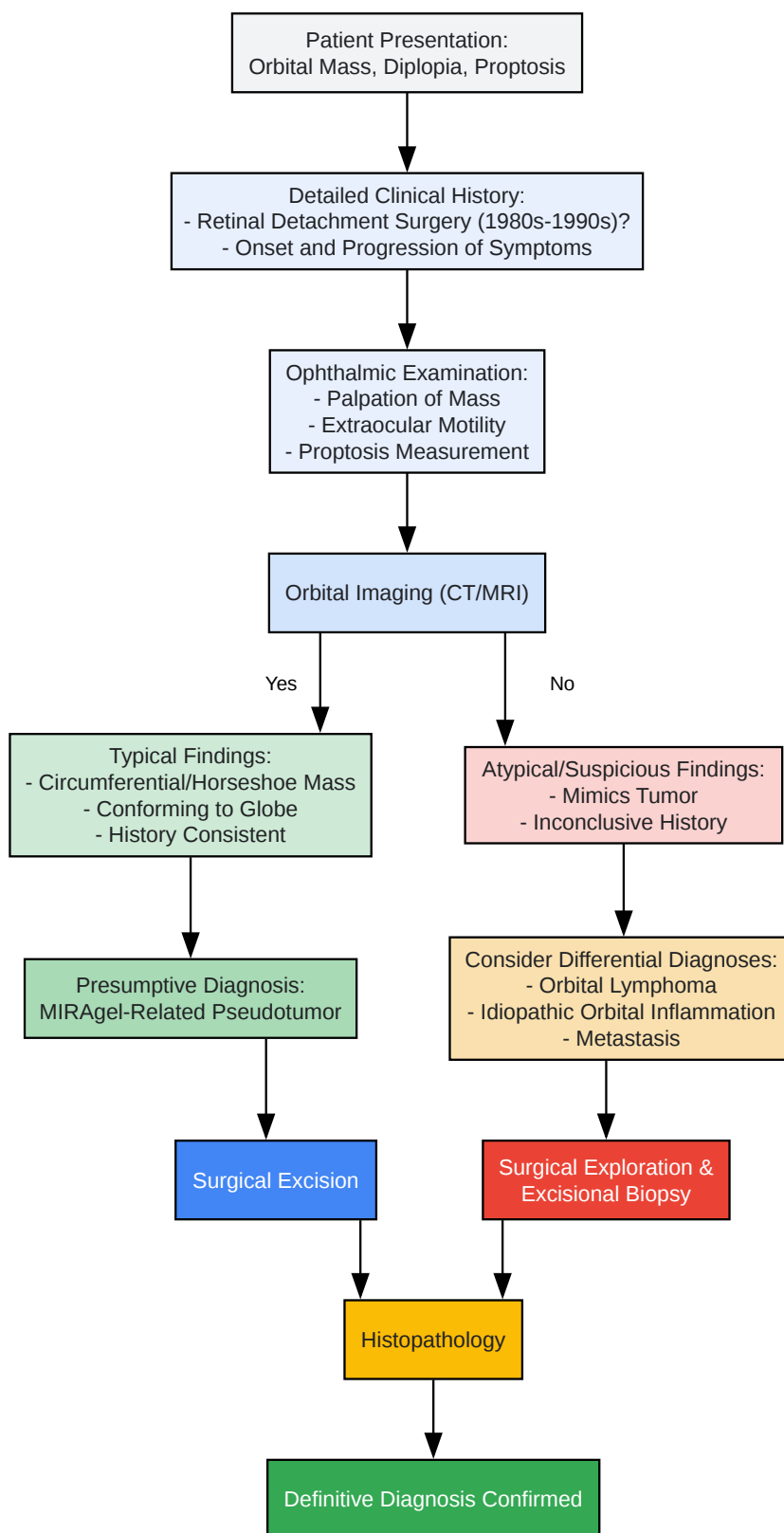
Objective: To confirm the identity of excised orbital material as hydrolyzed **MIRAgel** and to characterize the associated inflammatory response.

Methodology:

- Specimen Collection and Fixation:
 - During surgical excision, collect all visible fragments of the suspected **MIRAgel** material. Note the gross appearance (e.g., crumbly, whitish, gelatinous).
 - Immediately fix the tissue specimens in 10% neutral buffered formalin.
- Tissue Processing and Sectioning:
 - After adequate fixation, process the tissue through graded alcohols and xylene, and embed in paraffin wax.
 - Cut thin sections (4-5 micrometers) using a microtome and mount them on glass slides.
- Staining:
 - Hematoxylin and Eosin (H&E) Staining: This is the primary stain for observing the overall morphology.
 - Expected Findings: The **MIRAgel** material itself appears as eosinophilic, acellular sheets or fragments with a characteristic lattice-like or honeycomb architecture.^[5] The contents of the honeycomb lattice can be globular or granular.^[5] Surrounding the fragments, a foreign body granulomatous reaction is typically observed, characterized by multinucleated giant cells, macrophages (histiocytes), lymphocytes, and plasma cells.^{[5][12]}
 - Periodic Acid-Schiff (PAS) Staining: This stain is useful for highlighting the hydrogel material.

- Expected Findings: The contents within the **MIRAgel** lattice are strongly PAS-positive.
[\[5\]](#)
- Alcian Blue Staining: This stain is used to identify acidic mucopolysaccharides.
 - Expected Findings: The **MIRAgel** material is typically negative with Alcian blue staining.
[\[5\]](#)
- Immunohistochemistry (Optional):
 - To further characterize the inflammatory infiltrate, immunohistochemical staining for markers such as CD68 (macrophages), CD3 (T-lymphocytes), and CD20 (B-lymphocytes) can be performed.
 - Expected Findings: A predominance of CD68+ macrophages and CD3+ T-cells is consistent with a delayed T-cell mediated immune response to the foreign material.[\[12\]](#)
- Microscopic Examination and Reporting:
 - A pathologist should examine the stained slides to confirm the presence of the characteristic **MIRAgel** architecture and the nature of the inflammatory infiltrate.
 - The final report should describe these findings to confirm the diagnosis of a **MIRAgel** buckle-related orbital pseudotumor.

Mandatory Visualization



[Click to download full resolution via product page](#)

Caption: Diagnostic workflow for suspected **MIRAgel** buckle-related orbital pseudotumor.

Need Custom Synthesis?

BenchChem offers custom synthesis for rare earth carbides and specific isotopic labeling.

Email: info@benchchem.com or [Request Quote Online](#).

References

- 1. researchgate.net [researchgate.net]
- 2. Hydrogel (Miragel®) scleral explant, late orbital complication - PMC [pmc.ncbi.nlm.nih.gov]
- 3. New onset diplopia: 14 years after retinal detachment surgery with a hydrogel scleral buckle - PMC [pmc.ncbi.nlm.nih.gov]
- 4. Chronic Macular Oedema as a Late MIRAgel-Related Complication - PMC [pmc.ncbi.nlm.nih.gov]
- 5. Histopathology of Hydrolyzed MIRAgel Scleral Buckles - PMC [pmc.ncbi.nlm.nih.gov]
- 6. Clinical and radiographic features of hydrolyzed MIRAgel scleral buckles: A comparative analysis - PubMed [pubmed.ncbi.nlm.nih.gov]
- 7. Expanding MIRAgel scleral buckle simulating an orbital tumor in four cases - PubMed [pubmed.ncbi.nlm.nih.gov]
- 8. researchgate.net [researchgate.net]
- 9. MR Imaging of Orbital Inflammatory Pseudotumors with Extraorbital Extension - PMC [pmc.ncbi.nlm.nih.gov]
- 10. radiopaedia.org [radiopaedia.org]
- 11. Orbital inflammatory pseudotumor: new advances in diagnosis, pathogenesis, and treatment - PMC [pmc.ncbi.nlm.nih.gov]
- 12. researchgate.net [researchgate.net]
- 13. researchgate.net [researchgate.net]
- 14. Challenges in Diagnosing Extruded Hydrogel Scleral Buckle Mimicking an Orbital Abscess: A Case Report - PMC [pmc.ncbi.nlm.nih.gov]
- To cite this document: BenchChem. [Technical Support Center: Diagnosing MIRAgel Buckle-Related Orbital Pseudotumor]. BenchChem, [2025]. [Online PDF]. Available at: [https://www.benchchem.com/product/b1168782#diagnosing-miragel-buckle-related-orbital-pseudotumor]

Disclaimer & Data Validity:

The information provided in this document is for Research Use Only (RUO) and is strictly not intended for diagnostic or therapeutic procedures. While BenchChem strives to provide accurate protocols, we make no warranties, express or implied, regarding the fitness of this product for every specific experimental setup.

Technical Support: The protocols provided are for reference purposes. Unsure if this reagent suits your experiment? [[Contact our Ph.D. Support Team for a compatibility check](#)]

Need Industrial/Bulk Grade? [Request Custom Synthesis Quote](#)

BenchChem

Our mission is to be the trusted global source of essential and advanced chemicals, empowering scientists and researchers to drive progress in science and industry.

Contact

Address: 3281 E Guasti Rd
Ontario, CA 91761, United States
Phone: (601) 213-4426
Email: info@benchchem.com