

Radiographic Features of Hydrolyzed MIRAgel Buckles: An In-depth Technical Guide

Author: BenchChem Technical Support Team. **Date:** December 2025

Compound of Interest

Compound Name: *Miragel*

Cat. No.: *B1168782*

[Get Quote](#)

For Researchers, Scientists, and Drug Development Professionals

Abstract

MIRAgel (hydrogel) scleral buckles, once a common biomaterial for retinal detachment surgery, were discontinued due to long-term complications arising from in vivo hydrolysis.^[1] This degradation leads to buckle expansion, fragmentation, and a surrounding inflammatory response, often mimicking orbital pathologies like tumors or infections and delaying correct diagnosis and treatment.^{[1][2]} This technical guide provides a comprehensive overview of the distinct radiographic features of hydrolyzed **MIRAgel** buckles across various imaging modalities. It is intended to serve as a resource for researchers, scientists, and drug development professionals, offering detailed imaging characteristics, experimental protocols derived from clinical studies, and visual workflows to aid in the identification and understanding of this late complication.

Introduction

MIRAgel, a hydrophilic polymer (copoly[methyl acrylate-2 hydroxyethyl acrylate] crosslinked with ethylene diacrylate), was introduced in the 1980s as a soft and pliable alternative to silicone for scleral buckling procedures.^{[3][4]} However, over time, these buckles were found to undergo hydrolytic degradation, leading to significant swelling—sometimes up to four times their original volume—and fragmentation.^{[5][6]} Complications such as pain, limited extraocular motility, diplopia, infection, and scleral perforation can manifest years, or even decades, after implantation, necessitating surgical removal.^{[1][5][7]} Radiographic imaging is crucial for

diagnosing hydrolyzed **MIRAgel** buckles, differentiating them from other orbital masses, and planning for surgical intervention.[2][5]

Radiographic Presentations Across Imaging Modalities

The imaging appearance of a hydrolyzed **MIRAgel** buckle is characteristic and reflects its increased water content and the body's foreign body reaction.[7][8] The hallmark is a circumferential or localized mass encircling the globe, corresponding to the location of the original buckle.[7][8]

Computed Tomography (CT)

CT imaging is particularly valuable for identifying calcifications, a common feature of the chronic inflammatory response to the degraded material.[7][8]

- **Appearance:** A hydrolyzed **MIRAgel** buckle typically appears as a lobulated, circumferential soft-tissue mass around the globe.[3][9]
- **Attenuation:** The hydrated buckle material displays attenuation intermediate between fluid and soft tissue.[5]
- **Calcifications:** Dystrophic calcifications are a key finding and are best visualized on CT scans, appearing as chunk-like areas of hyperdensity within the mass.[3][7][8][9]
- **Enhancement:** After contrast administration, a fibrous capsule surrounding the fragmented buckle often shows rim enhancement.[5][7][8]

Magnetic Resonance Imaging (MRI)

MRI provides excellent soft-tissue contrast, making it ideal for delineating the extent of the buckle and its relationship to surrounding orbital structures.

- **Signal Characteristics:**
 - **T1-weighted images:** The expanded buckle is typically isointense to extraocular muscles.[6][7][8]

- T2-weighted images: Due to the high water content from hydrolysis, the buckle appears markedly hyperintense, similar to vitreous humor or cystic fluid.[6][7][8]
- Enhancement: Similar to CT, contrast-enhanced T1-weighted images often demonstrate an enhancing rim, which corresponds to the surrounding fibrous capsule.[6][7][8]
- Morphology: MRI can clearly show the expanded, often fragmented, and lobulated nature of the hydrolyzed buckle conforming to the globe.[6][7] A low-signal intensity rim may also be visible on T2-weighted images.[6]

Ultrasound

While less detailed than CT or MRI, ultrasonography can be a useful initial imaging modality.

- Appearance: A hydrated buckle is typically anechoic on ultrasonography.[5] It may appear as a cystic lesion in the orbit.[10][11]

Quantitative Data Summary

While specific Hounsfield Units (HU) for CT are not consistently reported in the literature, the descriptive characteristics are well-documented. The following tables summarize the key imaging features.

Table 1: CT Imaging Characteristics of Hydrolyzed **MIRAgel** Buckles

Feature	Description
Morphology	Lobulated, circumferential, or localized mass conforming to the globe.[3][7][9]
Attenuation	Intermediate between fluid and soft tissue.[5]
Calcifications	Often present; appear as chunk-like hyperdensities.[7][8]
Contrast Enhancement	Peripheral rim enhancement of the surrounding fibrous capsule.[5][7][8]

Table 2: MRI Signal Characteristics of Hydrolyzed **MIRAgel** Buckles

MRI Sequence	Signal Intensity
T1-Weighted	Isointense to extraocular muscle. [6] [7] [8]
T2-Weighted	Markedly hyperintense (similar to fluid/vitreous). [6] [7] [8]
Post-Contrast T1	Rim enhancement of the surrounding capsule. [6] [7] [8]

Experimental and Imaging Protocols

The following protocols are synthesized from methodologies described in the cited clinical studies.[\[7\]](#)

CT Imaging Protocol

- Scanner: Multidetector CT scanner.
- Acquisition: Thin-section (e.g., 1-2 mm) axial and coronal images of the orbits.
- Contrast: An intravenous iodinated contrast agent is administered for post-contrast scans to evaluate for enhancement.
- Reconstruction: Images are reconstructed using a soft-tissue algorithm.

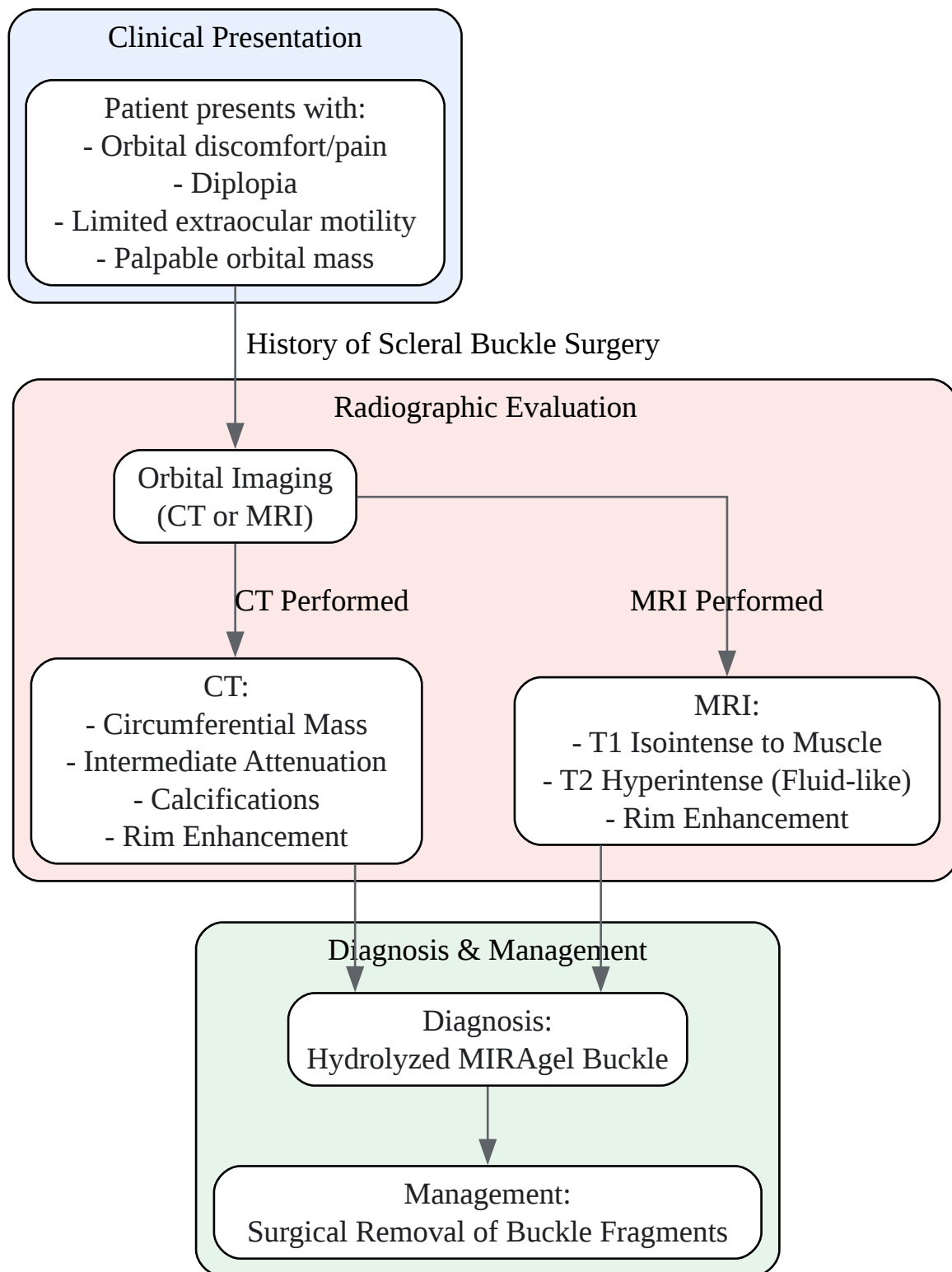
MRI Imaging Protocol

- Scanner: 1.5 Tesla (1.5T) or higher magnetic field strength scanner.[\[7\]](#)
- Coil: Dedicated orbital or head coil.
- Sequences:
 - Axial and coronal T1-weighted (e.g., TR/TE 500/15 ms).[\[7\]](#)
 - Axial and coronal T2-weighted (e.g., TR/TE 2000/80 ms), often with fat suppression.[\[7\]](#)

- Short-Tau Inversion Recovery (STIR) images can also be valuable for highlighting the high water content.[6]
- Contrast: Post-contrast axial and coronal T1-weighted sequences are obtained after administration of a gadolinium-based contrast agent.[7]

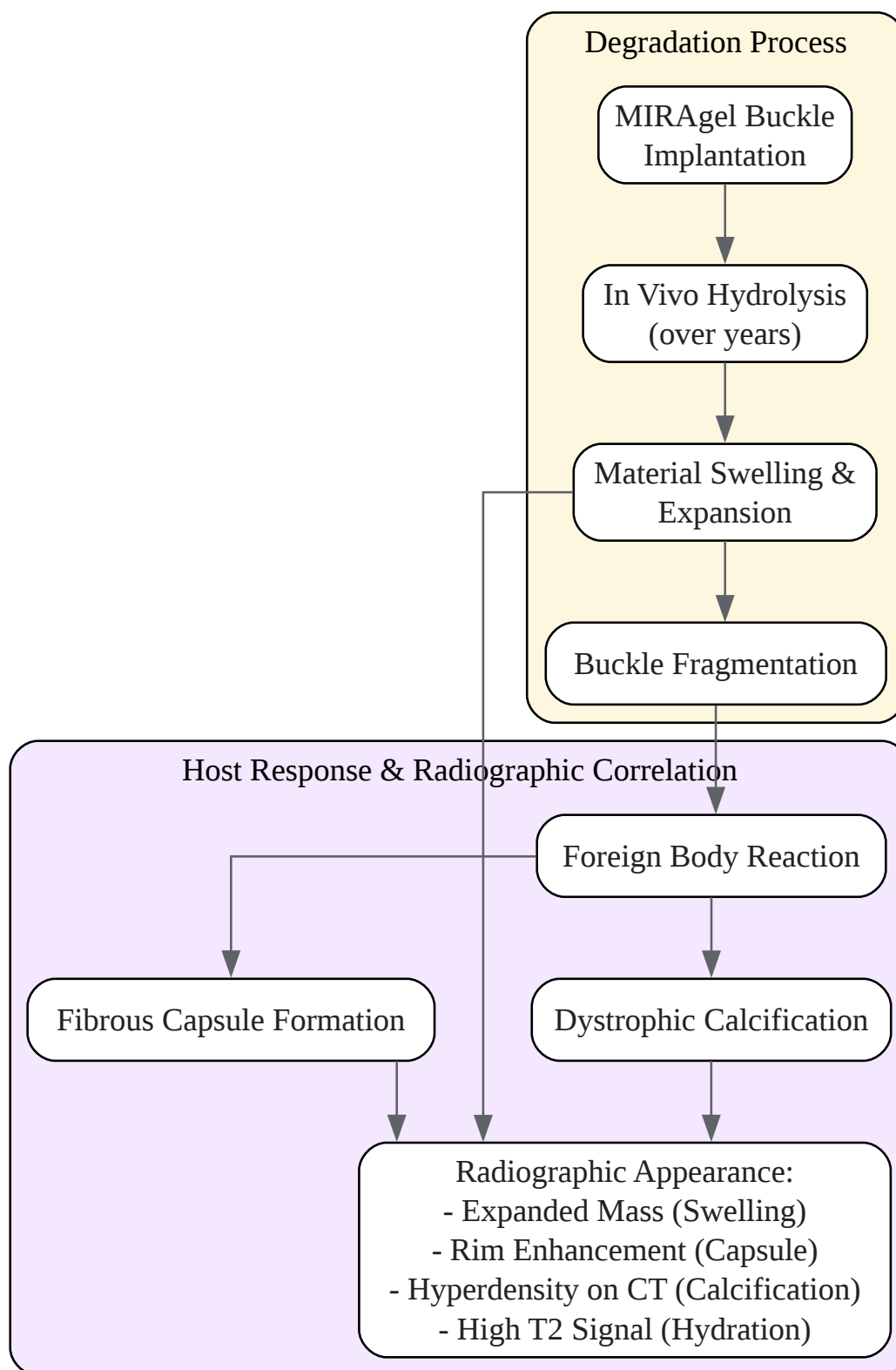
Visualizing Diagnostic and Clinical Workflows

The following diagrams illustrate the typical diagnostic workflow and the underlying pathophysiology.



[Click to download full resolution via product page](#)

Caption: Diagnostic workflow for a patient with a suspected hydrolyzed **MIRAgel** buckle.



[Click to download full resolution via product page](#)

Caption: Pathophysiological cascade of **MIRAgel** hydrolysis and its radiographic correlates.

Conclusion

The radiographic features of hydrolyzed **MIRAgel** scleral buckles are distinctive and, when correlated with a patient's surgical history, can lead to an accurate diagnosis.[1][2] Key imaging findings include an expanded, often fragmented, circumferential mass that is hyperintense on T2-weighted MRI and may show dystrophic calcification on CT, with a characteristic enhancing fibrous capsule.[5][6][7][8] Familiarity with these features is essential for radiologists, ophthalmologists, and researchers to differentiate this condition from other orbital pathologies and to guide appropriate surgical management. This guide provides the foundational knowledge for professionals involved in the study of biomaterial degradation and the development of new, more stable ophthalmic devices.

Need Custom Synthesis?

BenchChem offers custom synthesis for rare earth carbides and specific isotopic labeling.

Email: info@benchchem.com or [Request Quote Online](#).

References

- 1. Clinical and radiographic features of hydrolyzed MIRAgel scleral buckles: A comparative analysis - PubMed [pubmed.ncbi.nlm.nih.gov]
- 2. researchgate.net [researchgate.net]
- 3. karger.com [karger.com]
- 4. Chronic Macular Oedema as a Late MIRAgel-Related Complication - PMC [pmc.ncbi.nlm.nih.gov]
- 5. researchgate.net [researchgate.net]
- 6. kindai.repo.nii.ac.jp [kindai.repo.nii.ac.jp]
- 7. ajnr.org [ajnr.org]
- 8. Imaging of Hydrogel Episcleral Buckle Fragmentation as a Late Complication After Retinal Reattachment Surgery - PMC [pmc.ncbi.nlm.nih.gov]
- 9. Histopathology of Hydrolyzed MIRAgel Scleral Buckles - PMC [pmc.ncbi.nlm.nih.gov]
- 10. Hydrogel (Miragel®) scleral explant, late orbital complication - PubMed [pubmed.ncbi.nlm.nih.gov]

- 11. Hydrogel (Miragel®) scleral explant, late orbital complication - PMC
[pmc.ncbi.nlm.nih.gov]
- To cite this document: BenchChem. [Radiographic Features of Hydrolyzed MIRAgel Buckles: An In-depth Technical Guide]. BenchChem, [2025]. [Online PDF]. Available at:
[https://www.benchchem.com/product/b1168782#radiographic-features-of-hydrolyzed-miragel-buckles]

Disclaimer & Data Validity:

The information provided in this document is for Research Use Only (RUO) and is strictly not intended for diagnostic or therapeutic procedures. While BenchChem strives to provide accurate protocols, we make no warranties, express or implied, regarding the fitness of this product for every specific experimental setup.

Technical Support: The protocols provided are for reference purposes. Unsure if this reagent suits your experiment? [[Contact our Ph.D. Support Team for a compatibility check](#)]

Need Industrial/Bulk Grade? [Request Custom Synthesis Quote](#)

BenchChem

Our mission is to be the trusted global source of essential and advanced chemicals, empowering scientists and researchers to drive progress in science and industry.

Contact

Address: 3281 E Guasti Rd
Ontario, CA 91761, United States
Phone: (601) 213-4426
Email: info@benchchem.com