

Application Notes and Protocols for the Management of Diplopia Following MIRAgel Implantation

Author: BenchChem Technical Support Team. **Date:** December 2025

Compound of Interest

Compound Name: *Miragel*

Cat. No.: *B1168782*

[Get Quote](#)

For Researchers, Scientists, and Drug Development Professionals

Introduction

MIRAgel, a hydrogel explant, was utilized as a scleral buckling material for retinal detachment surgery primarily in the 1980s and early 1990s.[1] While initially favored for its pliability and perceived biocompatibility, long-term follow-up has revealed a significant complication profile.[2][3] The hydrophilic nature of **MIRAgel** leads to progressive swelling and degradation over time, resulting in a range of adverse effects including chronic pain, implant extrusion, and significant ocular motility disturbances leading to diplopia (double vision).[2][3][4] These complications can manifest decades after the initial surgery, posing a diagnostic and therapeutic challenge.[3]

This document provides a comprehensive overview of the management of diplopia secondary to **MIRAgel** implantation, intended for researchers, scientists, and professionals in drug development. It outlines the underlying pathophysiology, diagnostic protocols, and a structured approach to treatment, supported by quantitative data from published studies.

Pathophysiology of MIRAgel-Induced Diplopia

The primary cause of diplopia in patients with a **MIRAgel** scleral buckle is the progressive and significant increase in the implant's volume.[1][2] This expansion is a result of the hydrolysis of

the poly(2-hydroxyethyl methacrylate) material, causing it to absorb water and swell to several times its original size.[2][3] The enlarged implant can:

- Mechanically restrict extraocular muscles: The expanding mass can impinge upon and limit the movement of one or more extraocular muscles, leading to incomitant strabismus.[1][3][4]
- Cause a mass effect: The sheer volume of the swollen implant can displace the globe and surrounding orbital tissues, altering ocular alignment.[2]
- Induce inflammation and fibrosis: Chronic irritation from the degrading implant can lead to inflammation and the formation of a fibrous pseudocapsule, further tethering orbital structures.[4]

Diagnostic Protocols

A systematic approach is crucial for the accurate diagnosis of **MIRAgel**-related diplopia and for planning appropriate management.

Patient History and Clinical Examination

A thorough history should be obtained, focusing on the original retinal detachment surgery, the type of scleral buckle used (if known), and the onset and characteristics of the diplopia. The clinical examination should include:

- Visual Acuity and Refraction: To assess for any concurrent visual compromise.
- Ocular Motility Assessment: To determine the pattern of motility restriction and the positions of gaze where diplopia is most pronounced.
- Strabismus Measurement: Using prism and alternate cover testing in all cardinal positions of gaze to quantify the deviation.
- Forced Duction Test: To differentiate between a restrictive myopathy (mechanical limitation) and a paretic muscle. In **MIRAgel**-induced diplopia, a positive forced duction test is expected, indicating a mechanical restriction.
- Slit-lamp Examination: To look for signs of implant exposure, conjunctival thinning, or inflammation.

- Palpation of the Orbit: To detect any palpable mass corresponding to the swollen implant.

Imaging Studies

Orbital imaging is essential to visualize the expanded **MIRAgel** implant and its relationship to the extraocular muscles and other orbital structures.

- Computed Tomography (CT): Provides excellent anatomical detail of the orbit, demonstrating the size and location of the swollen hydrogel implant, which often appears as a well-defined, circumferential soft tissue mass around the globe.^[1] CT can also reveal associated complications like scleral thinning or erosion.
- Magnetic Resonance Imaging (MRI): Offers superior soft tissue contrast and can further delineate the extent of the implant and its impact on the extraocular muscles.

Management Strategies

The management of diplopia secondary to **MIRAgel** implantation is often challenging and may require a multi-pronged approach. Treatment is typically initiated when the diplopia becomes persistent and significantly impacts the patient's quality of life.^[5]

Non-Surgical Management

Non-surgical options are generally considered for patients with smaller, comitant deviations or as a temporizing measure.

- Prism Therapy: Fresnel or ground-in prisms can be used to optically realign the images and alleviate diplopia in the primary position of gaze.^{[5][6][7]} However, their effectiveness may be limited in cases of significant incomitance.
- Occlusion: In cases of intractable diplopia, occlusion of one eye (e.g., with a patch or frosted lens) can eliminate the double vision, although this results in the loss of binocular vision and depth perception.^[7]

Surgical Management

Surgical intervention is often necessary for definitive treatment, especially in cases with significant motility restriction and a large, swollen implant.

- **MIRAgel Implant Removal:** This is the primary surgical intervention aimed at relieving the mechanical restriction.^{[2][8]} However, the procedure can be challenging due to the friable nature of the degraded implant and the risk of scleral thinning or perforation.^{[1][2]} A retinal surgeon's involvement may be beneficial.^[1]
- **Strabismus Surgery:** If diplopia persists after implant removal, or if removal is deemed too risky, strabismus surgery on the extraocular muscles can be performed to realign the eyes.^{[9][10]} This may involve recession or resection of the rectus muscles.

Quantitative Data on Diplopia and Treatment Outcomes

Parameter	Finding	Reference
Incidence of Diplopia		
Persistent diplopia post-scleral buckle (general)	0.5% - 25%	[5]
Diplopia as a reason for MIRAgel removal	30% in one study of 23 eyes	[2]
Diplopia and strabismus in a series of 17 eyes with MIRAgel complications	10 of 17 eyes	[3]
Treatment Outcomes		
Successful treatment with prisms (general post-scleral buckle)	17 of 26 patients in one series	[6]
Restoration of binocular single vision after buckle removal (general)	6 of 12 patients in one study	[9]
Restoration of binocular vision with prisms after buckle removal	3 additional patients in the same study	[9]
Need for strabismus surgery after buckle removal	3 patients in the same study	[9]

Experimental Protocols

Protocol 1: Forced Duction Test

Objective: To differentiate between restrictive and paretic strabismus.

Materials:

- Topical anesthetic drops (e.g., proparacaine hydrochloride 0.5%)
- Fine-toothed forceps (e.g., Bishop-Harmon)

- Cotton-tipped applicators

Procedure:

- Instill 1-2 drops of topical anesthetic into the conjunctival sac of the affected eye. Wait 1-2 minutes for the anesthetic to take effect.
- Ask the patient to look in the direction opposite to the suspected restriction.
- Gently grasp the conjunctiva and Tenon's capsule near the limbus with the forceps at the insertion of the muscle to be tested.
- Attempt to passively move the globe in the direction of the suspected restriction.
- Interpretation:
 - Positive Test (Restriction): Inability to move the globe freely indicates a mechanical restriction. This is the expected finding in **MIRAgel**-induced diplopia.
 - Negative Test (No Restriction): The globe can be moved freely, suggesting a paretic or weak muscle.

Protocol 2: Surgical Removal of MIRAgel Implant

Objective: To decompress the orbit and relieve mechanical restriction of the extraocular muscles.

Materials:

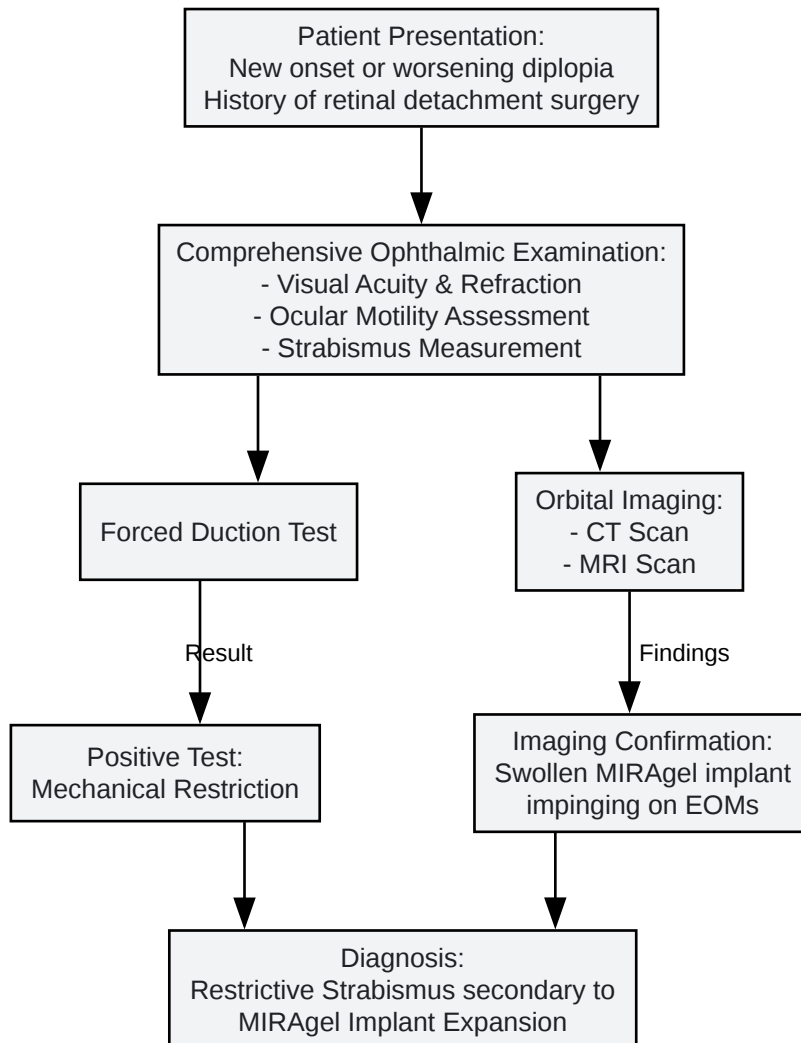
- Standard ophthalmic surgical instrument set
- Operating microscope
- Cryotherapy or diathermy unit
- Sutures (e.g., 6-0 Vicryl, 8-0 Nylon)
- Viscoelastic device

Procedure:

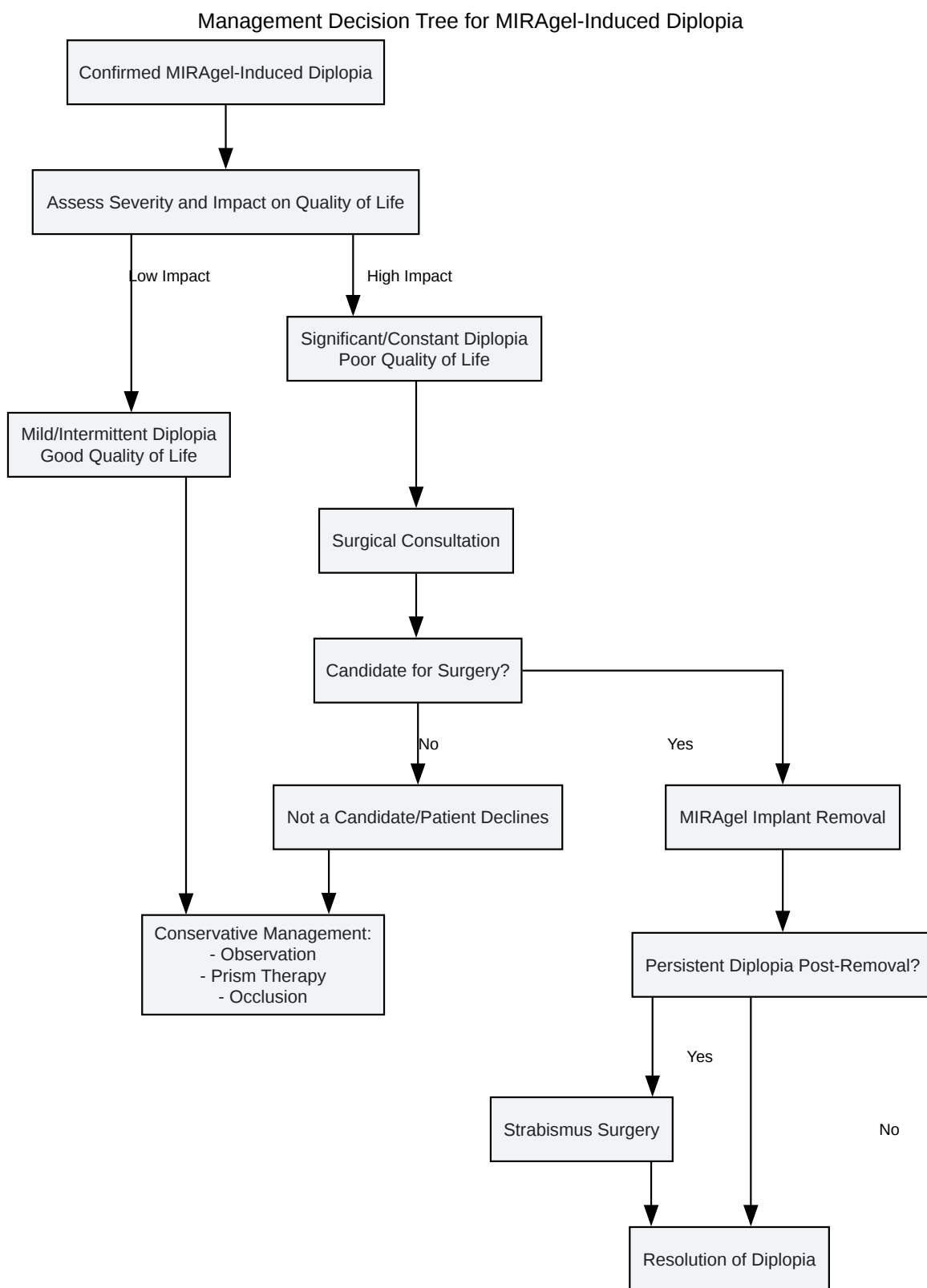
- Perform a peritomy to expose the sclera and the **MIRAgel** implant.
- Carefully dissect the conjunctiva and Tenon's capsule off the implant. A pseudocapsule is often present and needs to be incised.
- Identify and isolate the extraocular muscles that may be adherent to the implant.
- The **MIRAgel** implant will likely be swollen and friable. Meticulously remove the implant in a piecemeal fashion using forceps and a spatula. Avoid excessive traction to prevent scleral damage.
- Thoroughly inspect the underlying sclera for any signs of thinning or necrosis. If a scleral defect is present, it may need to be repaired with a scleral patch graft.
- Ensure complete removal of all implant fragments to prevent recurrent inflammation.
- Re-evaluate ocular motility intraoperatively using forced ductions after implant removal.
- Close the conjunctiva with absorbable sutures.

Visualized Workflows

Diagnostic Workflow for Post-MIRAgel Diplopia

[Click to download full resolution via product page](#)

Caption: Diagnostic workflow for post-**MIRAgel** diplopia.



[Click to download full resolution via product page](#)

Caption: Management decision tree for **MIRAgel**-induced diplopia.

Need Custom Synthesis?

BenchChem offers custom synthesis for rare earth carbides and specific isotopic labeling.

Email: info@benchchem.com or [Request Quote Online](#).

References

- 1. New onset diplopia: 14 years after retinal detachment surgery with a hydrogel scleral buckle - PMC [[pmc.ncbi.nlm.nih.gov](https://pubmed.ncbi.nlm.nih.gov)]
- 2. researchgate.net [researchgate.net]
- 3. Hydrogel (Miragel®) scleral explant, late orbital complication - PMC [[pmc.ncbi.nlm.nih.gov](https://pubmed.ncbi.nlm.nih.gov)]
- 4. Management of Delayed Complications of Hydrogel Scleral Buckles - PMC [[pmc.ncbi.nlm.nih.gov](https://pubmed.ncbi.nlm.nih.gov)]
- 5. ovjournal.org [ovjournal.org]
- 6. iovs.arvojournals.org [iovs.arvojournals.org]
- 7. Nonsurgical management of diplopia - PubMed [pubmed.ncbi.nlm.nih.gov]
- 8. Management of complex retinal detachment from intraocular invasion of MIRAgel-a case report - PMC [[pmc.ncbi.nlm.nih.gov](https://pubmed.ncbi.nlm.nih.gov)]
- 9. [Diplopia complicating scleral buckling surgery for retinal detachment] - PubMed [pubmed.ncbi.nlm.nih.gov]
- 10. quora.com [quora.com]
- To cite this document: BenchChem. [Application Notes and Protocols for the Management of Diplopia Following MIRAgel Implantation]. BenchChem, [2025]. [Online PDF]. Available at: [<https://www.benchchem.com/product/b1168782#managing-diplopia-after-miragel-implantation>]

Disclaimer & Data Validity:

The information provided in this document is for Research Use Only (RUO) and is strictly not intended for diagnostic or therapeutic procedures. While BenchChem strives to provide accurate protocols, we make no warranties, express or implied, regarding the fitness of this product for every specific experimental setup.

Technical Support: The protocols provided are for reference purposes. Unsure if this reagent suits your experiment? [[Contact our Ph.D. Support Team for a compatibility check](#)]

Need Industrial/Bulk Grade? [Request Custom Synthesis Quote](#)

BenchChem

Our mission is to be the trusted global source of essential and advanced chemicals, empowering scientists and researchers to drive progress in science and industry.

Contact

Address: 3281 E Guasti Rd
Ontario, CA 91761, United States
Phone: (601) 213-4426
Email: info@benchchem.com