

Application Notes and Protocols for Imaging MIRAgel Scleral Buckle Expansion

Author: BenchChem Technical Support Team. **Date:** December 2025

Compound of Interest

Compound Name: *Miragel*

Cat. No.: *B1168782*

[Get Quote](#)

For Researchers, Scientists, and Drug Development Professionals

Introduction

MIRAgel, a hydrogel-based material, was utilized for scleral buckling procedures in the treatment of rhegmatogenous retinal detachment.[1][2][3] Although initially promising due to its pliability and potential for antibiotic absorption, long-term follow-up has revealed a significant complication: hydrolytic degradation of the material leading to substantial expansion.[1][2][3] This expansion can cause a range of clinical issues including diplopia, proptosis, globe displacement, and pain, often mimicking an orbital mass.[4][5] Accurate and timely detection of **MIRAgel** buckle expansion is crucial for appropriate patient management, which often involves surgical removal of the degraded implant.[3][5]

These application notes provide detailed protocols for various imaging modalities used to detect and characterize the expansion of **MIRAgel** scleral buckles. The information is intended to guide researchers and clinicians in the selection and application of appropriate imaging techniques and in the interpretation of findings.

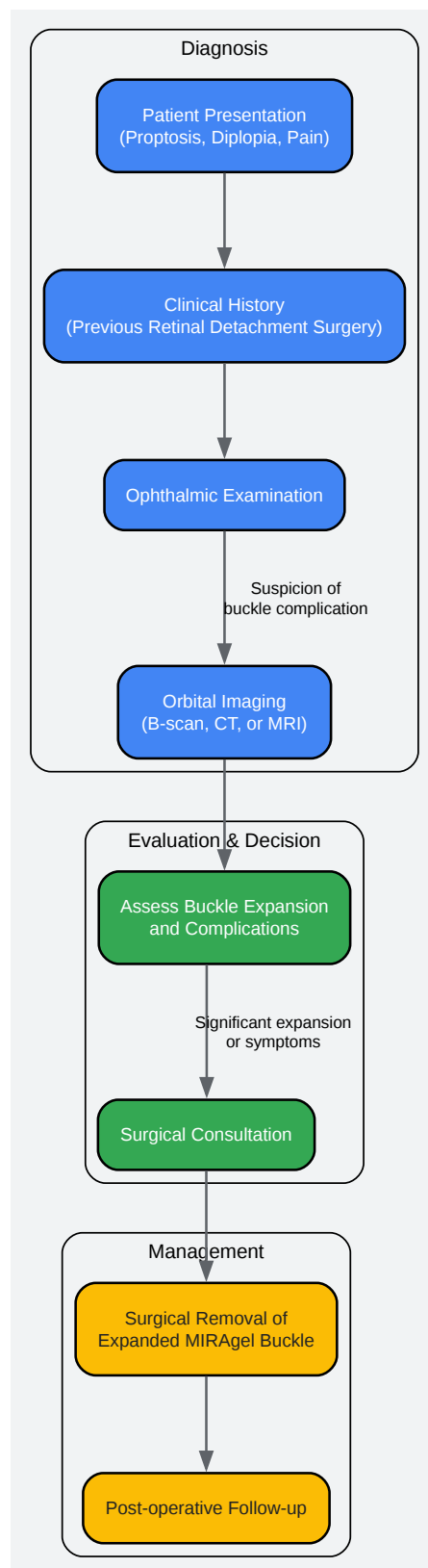
Mechanism of MIRAgel Buckle Expansion

The expansion of **MIRAgel** scleral buckles is a result of in-vivo hydrolysis.[1] The hydrogel material absorbs water over time, leading to a change in its physical properties. The once soft and spongy implant becomes friable, gel-like, and translucent, and can expand to several times its original size.[4][6] This process is a slow degradation, with complications typically presenting

7 to 20 years after the initial surgery.[5][7] The expanded buckle can incite a foreign body granulomatous reaction, further contributing to the mass effect and clinical symptoms.[5]

Clinical Workflow for Suspected MIRAgel Buckle Expansion

The following diagram outlines the typical clinical workflow for a patient presenting with symptoms suggestive of **MIRAgel** buckle expansion.



[Click to download full resolution via product page](#)

Clinical workflow for **MIRAgel** buckle expansion.

Experimental Imaging Protocols

The following are recommended starting protocols for imaging suspected **MIRAgel** buckle expansion. These should be adapted based on the available equipment and specific clinical questions.

B-Scan Ultrasonography

B-scan ultrasonography is a readily available and non-invasive imaging modality that can provide valuable initial information about the presence and characteristics of an expanded **MIRAgel** buckle.

Methodology:

- **Patient Preparation:** The patient is typically examined in a supine position. Topical anesthetic drops are applied to the ocular surface.
- **Probe Selection:** A high-frequency (10-20 MHz) probe is used for optimal resolution of orbital structures.
- **Coupling Gel:** A generous amount of methylcellulose or other acoustic coupling gel is applied to the tip of the probe.
- **Scanning Technique:** The probe is placed directly on the globe or eyelids. A systematic screening of all quadrants of the globe is performed. Transverse, longitudinal, and axial scans should be obtained to fully characterize the lesion.
- **Image Acquisition:** Images are captured to document the location, size, shape, and echogenicity of the expanded buckle.

Data Presentation:

Parameter	Typical Finding for Expanded MIRAgel Buckle
Echogenicity	Anechoic (echo-lucent) mass in the episcleral region.[2][6]
Shape	Typically follows the contour of the globe, appearing as a circumferential or localized mass.
Internal Structure	May appear cystic or have low-level internal echoes.
Scleral Indentation	The degree of scleral indentation from the original buckling procedure may be altered or obscured by the expansion.

Computed Tomography (CT)

CT is an excellent modality for visualizing the overall size and extent of the expanded buckle, its relationship to adjacent structures, and for detecting the presence of calcifications.

Methodology:

- **Patient Positioning:** The patient is positioned supine in the CT scanner with the head carefully immobilized.
- **Scan Acquisition:** Axial and coronal images of the orbits are acquired.
- **Slice Thickness:** Thin slices (1-3 mm) are recommended for detailed evaluation.
- **Contrast Administration:** Intravenous contrast is generally not necessary for the initial detection of **MIRAgel** expansion but can be useful to evaluate for associated inflammation or to differentiate it from other orbital pathologies. If used, a non-ionic iodinated contrast agent is administered.
- **Image Reconstruction:** Images should be reconstructed with both soft tissue and bone algorithms.

Data Presentation:

Parameter	Typical Finding for Expanded MIRAgel Buckle
Attenuation	Appears as a well-circumscribed, bulky soft-tissue attenuation structure encircling the globe. [4] The density is often intermediate between fluid and soft tissue.
Enhancement	A peripheral rim of enhancement may be seen after contrast administration, corresponding to a fibrous capsule.[1]
Calcifications	Dystrophic, chunk-like calcifications may be present within the expanded material.[1]
Bone Changes	May cause smooth remodeling or erosion of the adjacent orbital bones in cases of significant expansion.[4]

Magnetic Resonance Imaging (MRI)

MRI offers superior soft-tissue contrast and is highly effective in characterizing the nature of the expanded **MIRAgel** material.

Methodology:

- Patient Preparation: The patient is screened for any contraindications to MRI.
- Coil: A head coil or dedicated orbital surface coils are used.
- Pulse Sequences: A multi-sequence protocol is recommended:
 - T1-weighted images (T1WI): Provide anatomical detail.
 - T2-weighted images (T2WI): Highly sensitive for detecting the fluid content of the expanded hydrogel.

- Fat-suppressed T2-weighted images (e.g., STIR or T2-FS): Improves the conspicuity of the lesion by suppressing the bright signal from orbital fat.
- Post-contrast fat-suppressed T1-weighted images (T1WI+C FS): To evaluate for an enhancing capsule and to differentiate from other enhancing orbital lesions.
- Imaging Planes: Axial, coronal, and sagittal planes should be acquired.
- Slice Thickness: Thin slices (2-3 mm) are optimal.

Data Presentation:

MRI Sequence	Typical Signal Characteristics for Expanded MIRAgel Buckle
T1-weighted (T1WI)	Isointense to extraocular muscles.[1][8]
T2-weighted (T2WI)	Markedly hyperintense, similar to fluid, due to the high water content of the expanded hydrogel.[1][8]
Post-contrast T1WI (Fat-Suppressed)	A low signal intensity rim may be observed.[8] A peripherally enhancing capsule may be present.[1]

Quantitative Data on MIRAgel Buckle Expansion

Quantitative data on the extent of **MIRAgel** buckle expansion is limited in the literature. However, case reports provide some insight into the potential degree of enlargement.

Imaging Modality	Reported Quantitative Findings
Computed Tomography (CT)	An expanded buckle was noted to be 4 times thicker than the contralateral non-expanded portion. [2]
Ocular Ultrasonography	An echolucent mass was observed that was 2 times thicker than the nasal scleral buckle. [2]
Magnetic Resonance Imaging (MRI)	A degenerated hydrogel buckle was described as having expanded 4-fold in volume. [8]

Histopathology

For a definitive diagnosis, especially in atypical cases, surgical excision and histopathological examination may be necessary. The explanted material typically appears as a friable, gelatinous, and clear-to-white substance. Microscopic examination reveals a foreign material with a characteristic honeycomb or lattice-like structure.[\[9\]](#)

Signaling Pathways and Biological Mechanisms

The expansion of **MIRAgel** is primarily a physicochemical process of hydrolysis and not driven by specific biological signaling pathways.[\[1\]](#) The subsequent clinical manifestations are due to a mass effect and a chronic foreign body inflammatory response to the degraded polymer.[\[5\]](#) This inflammatory reaction is a T-cell mediated immune response, with macrophages attempting to phagocytose the **MIRAgel** fragments.[\[5\]](#) Therefore, a diagram illustrating a specific signaling cascade is not applicable. The clinical workflow diagram provided above is a more relevant visualization for understanding the diagnostic and management process.

Conclusion

The long-term expansion of **MIRAgel** scleral buckles is a significant clinical concern for patients who underwent this procedure. A multi-modality imaging approach, incorporating B-scan ultrasonography, CT, and MRI, is essential for accurate diagnosis and pre-operative planning. The protocols and characteristic findings outlined in these application notes provide a comprehensive guide for researchers and clinicians involved in the evaluation of this condition. While quantitative data remains sparse, the qualitative imaging features are often

pathognomonic and crucial for differentiating **MIRAgel** buckle expansion from other orbital pathologies.

Need Custom Synthesis?

BenchChem offers custom synthesis for rare earth carbides and specific isotopic labeling.

Email: info@benchchem.com or [Request Quote Online](#).

References

- 1. Imaging of Hydrogel Episcleral Buckle Fragmentation as a Late Complication After Retinal Reattachment Surgery - PMC [pmc.ncbi.nlm.nih.gov]
- 2. Expanding MIRAgel scleral buckle simulating an orbital tumor in four cases - PubMed [pubmed.ncbi.nlm.nih.gov]
- 3. researchgate.net [researchgate.net]
- 4. Hydrogel (Miragel®) scleral explant, late orbital complication - PMC [pmc.ncbi.nlm.nih.gov]
- 5. Chronic Macular Oedema as a Late MIRAgel-Related Complication - PMC [pmc.ncbi.nlm.nih.gov]
- 6. Globe Loss from Intraocular Invasion of MIRAgel Scleral Buckle Components - PMC [pmc.ncbi.nlm.nih.gov]
- 7. Expansion of the MIRAgel Scleral Buckle With Findings Resembling Necrotizing Scleritis: A Case Report - PMC [pmc.ncbi.nlm.nih.gov]
- 8. kindai.repo.nii.ac.jp [kindai.repo.nii.ac.jp]
- 9. Histopathology of Hydrolyzed MIRAgel Scleral Buckles - PMC [pmc.ncbi.nlm.nih.gov]
- To cite this document: BenchChem. [Application Notes and Protocols for Imaging MIRAgel Scleral Buckle Expansion]. BenchChem, [2025]. [Online PDF]. Available at: [https://www.benchchem.com/product/b1168782#imaging-protocols-for-detecting-miragel-buckle-expansion]

Disclaimer & Data Validity:

The information provided in this document is for Research Use Only (RUO) and is strictly not intended for diagnostic or therapeutic procedures. While BenchChem strives to provide

accurate protocols, we make no warranties, express or implied, regarding the fitness of this product for every specific experimental setup.

Technical Support: The protocols provided are for reference purposes. Unsure if this reagent suits your experiment? [[Contact our Ph.D. Support Team for a compatibility check](#)]

Need Industrial/Bulk Grade? [Request Custom Synthesis Quote](#)

BenchChem

Our mission is to be the trusted global source of essential and advanced chemicals, empowering scientists and researchers to drive progress in science and industry.

Contact

Address: 3281 E Guasti Rd
Ontario, CA 91761, United States
Phone: (601) 213-4426
Email: info@benchchem.com