

A Head-to-Head Battle in Inflammation Imaging: Gallium Citrate vs. FDG PET

Author: BenchChem Technical Support Team. **Date:** December 2025

Compound of Interest

Compound Name: Gallium citrate

Cat. No.: B10776400

[Get Quote](#)

For researchers, scientists, and drug development professionals navigating the landscape of in vivo inflammation imaging, the choice between Gallium-67 citrate and F-18 fluorodeoxyglucose (FDG) positron emission tomography (PET) is a critical one. This guide provides an objective comparison of their performance, supported by experimental data, to inform the selection of the most appropriate imaging agent for specific research and clinical applications.

Gallium-67 (Ga-67) citrate, a traditional radiopharmaceutical for inflammation and tumor imaging, finds its utility in its ability to mimic iron, allowing it to localize in areas of infection and inflammation. In contrast, FDG PET, a more modern and widely adopted technique, leverages the increased glucose metabolism characteristic of inflammatory cells. This fundamental difference in their mechanisms of uptake dictates their respective strengths and weaknesses in clinical and research settings.

Performance Deep Dive: A Quantitative Comparison

To facilitate a clear comparison, the following tables summarize the quantitative performance of Gallium-67 citrate and FDG PET in various inflammatory conditions based on published studies.

| Radiopharmaceutical | Indication | Sensitivity (%) | Specificity (%) | Key Findings & Citations |
|---------------------|-------------------------------|-----------------|-----------------|---|
| Gallium-67 Citrate | Fever of Unknown Origin (FUO) | 67 | 78 | FDG PET was found to be superior in a prospective comparison.[1][2] |
| FDG PET | Fever of Unknown Origin (FUO) | 81 - 84 | 86 | Demonstrated higher sensitivity and diagnostic contribution compared to Gallium-67.[1][2][3] A multicenter study showed FDG-PET/CT had a significantly higher sensitivity (45%) than 67Ga-SPECT (25%).[4] |
| Gallium-67 Citrate | Sarcoidosis | 81 (pulmonary) | - | FDG PET detected more lesions overall.[5] In another study, FDG-PET was positive in 97% of patients, while Gallium-67 was positive in only 25.7%. [6] |
| FDG PET | Sarcoidosis | 100 (pulmonary) | - | Appears to be more accurate for evaluating |

| | | | | |
|--------------------|----------------------|-----|-----|--|
| | | | | extrapulmonary involvement.[5] |
| | | | | Detected a higher number of lesions compared to Gallium-67.[7][8] |
| Gallium-67 Citrate | Spinal Osteomyelitis | >90 | >90 | Considered a good alternative to MRI in this specific indication.[9] |
| FDG PET | Spinal Osteomyelitis | - | - | Has shown superiority to Gallium-67 citrate scanning and bone scintigraphy.[9] |

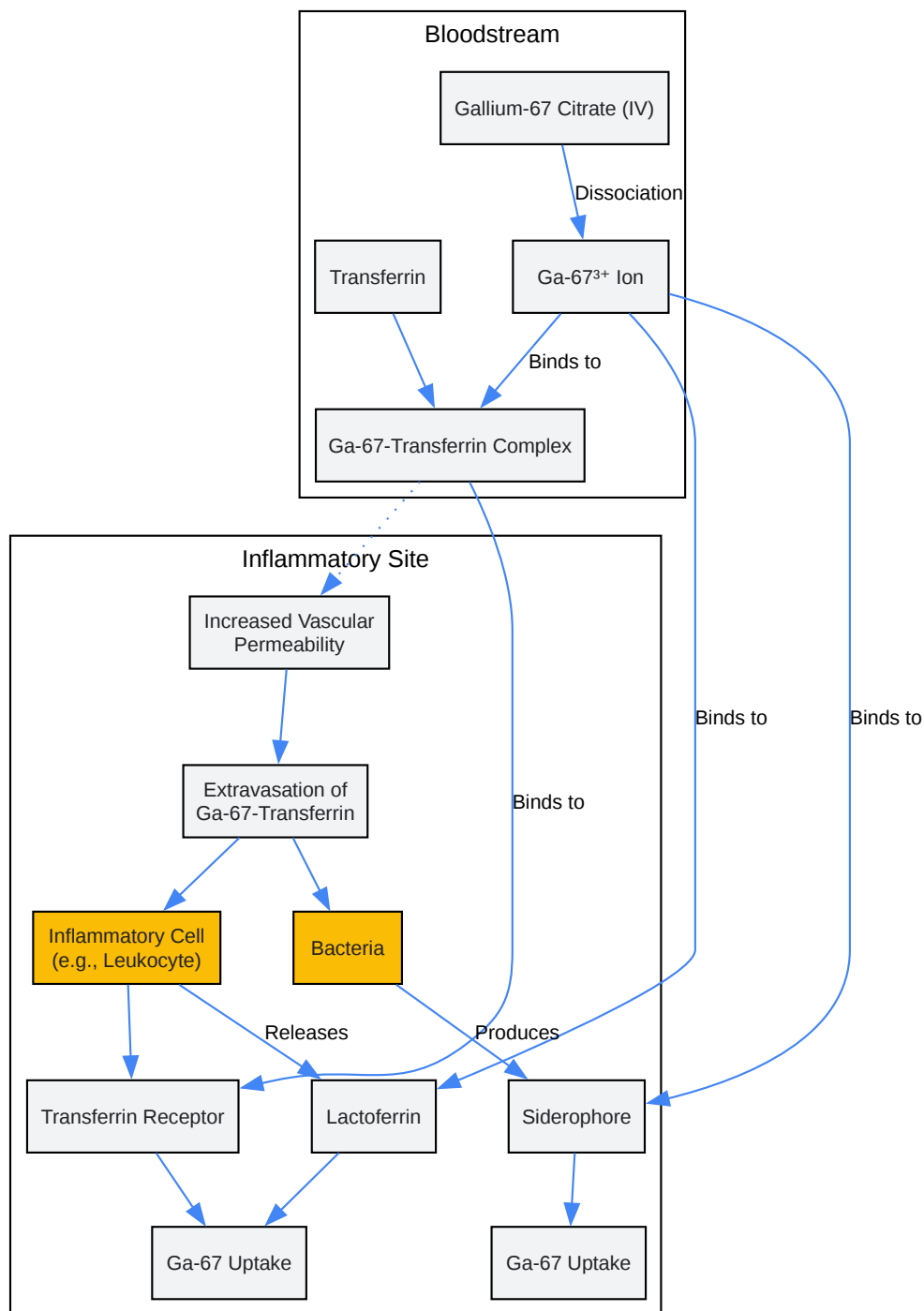
Mechanisms of Uptake: A Tale of Two Pathways

The distinct mechanisms by which Gallium-67 citrate and FDG accumulate in inflammatory foci are crucial to understanding their imaging characteristics.

Gallium-67 Citrate Uptake Pathway

Gallium-67's localization at sites of inflammation is a multi-factorial process primarily driven by its similarity to the ferric iron ion (Fe^{3+}).^[10] After intravenous administration, Ga-67 citrate dissociates, and the Ga-67 cation binds to transferrin in the plasma. This Ga-67-transferrin complex is then transported to areas of inflammation. The increased blood flow and vascular permeability at these sites facilitate the extravasation of the complex. Once in the inflamed tissue, Ga-67 can be taken up by inflammatory cells, such as leukocytes, and bacteria.^[11] This uptake is mediated by transferrin receptors on these cells, as well as binding to lactoferrin released by neutrophils and siderophores produced by bacteria.^[11]

Gallium-67 Citrate Uptake Mechanism

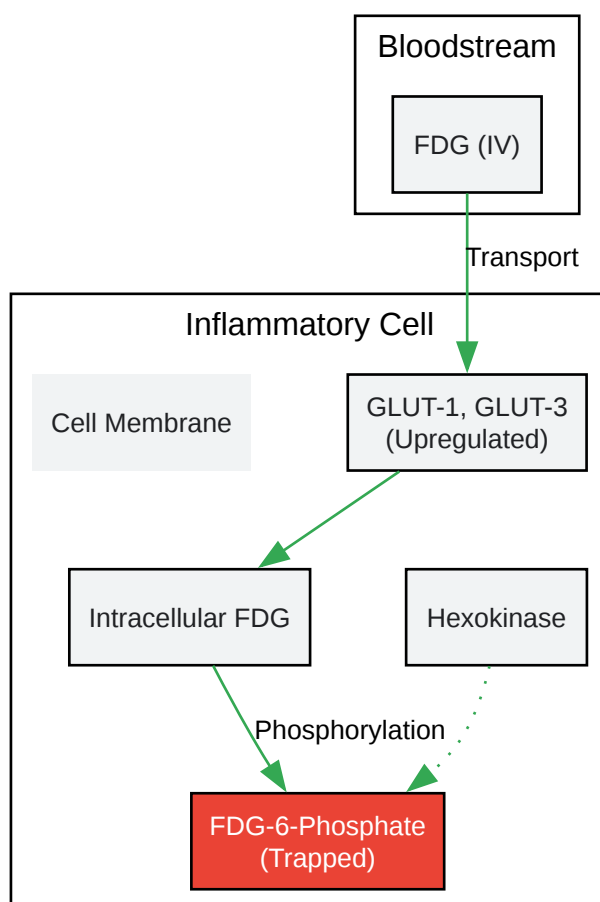
[Click to download full resolution via product page](#)

Gallium-67 Citrate Uptake Mechanism

FDG Uptake Pathway

FDG uptake is a direct reflection of the metabolic activity of inflammatory cells. Activated immune cells, including neutrophils, macrophages, and lymphocytes, exhibit a heightened rate of glucose consumption. This is facilitated by the overexpression of glucose transporter proteins (GLUT1 and GLUT3) on their cell membranes.^[12] Following intravenous injection, FDG, a glucose analog, is transported into these cells via GLUT transporters. Inside the cell, FDG is phosphorylated by the enzyme hexokinase to FDG-6-phosphate. Unlike glucose-6-phosphate, FDG-6-phosphate cannot be further metabolized in the glycolytic pathway and becomes trapped within the cell. This intracellular accumulation of FDG-6-phosphate is what is detected by the PET scanner.

FDG Uptake Mechanism in Inflammatory Cells



[Click to download full resolution via product page](#)

FDG Uptake Mechanism in Inflammatory Cells

Experimental Protocols: A Step-by-Step Guide

The successful application of these imaging techniques relies on meticulous adherence to established protocols.

Gallium-67 Citrate Scintigraphy

Patient Preparation:

- Bowel preparation with laxatives or enemas is often recommended to reduce physiologic bowel activity, which can interfere with image interpretation.[13]
- No specific dietary restrictions are typically required, but good hydration is encouraged.[14]

Radiopharmaceutical Administration and Dosage:

- Adults: 150–220 MBq (4–6 mCi) of Gallium-67 citrate administered intravenously.[13]
- Children: 1.5–2.6 MBq/kg (0.04–0.07 mCi/kg).[13]

Imaging Acquisition:

- Imaging is typically performed 18 to 72 hours after injection to allow for clearance of background activity.[15] Early imaging at 4-6 hours may be useful in cases of acute inflammation to minimize bowel activity.[16]
- A gamma camera equipped with a medium-energy collimator is used.
- Planar whole-body scans, as well as regional static and SPECT (Single Photon Emission Computed Tomography) images of specific areas of interest, are acquired.[13]

FDG PET/CT

Patient Preparation:

- Patients are required to fast for at least 6 hours prior to the scan to minimize physiologic glucose uptake in non-target tissues.
- Blood glucose levels should be checked before FDG injection and should ideally be below a certain threshold (e.g., < 7.0 mmol/L) as hyperglycemia can competitively inhibit FDG uptake.
- Patients should avoid strenuous exercise for 24 hours before the scan.

Radiopharmaceutical Administration and Dosage:

- The typical adult dose of F-18 FDG is weight-based, generally in the range of 3.7-7.4 MBq/kg (0.1-0.2 mCi/kg), administered intravenously.

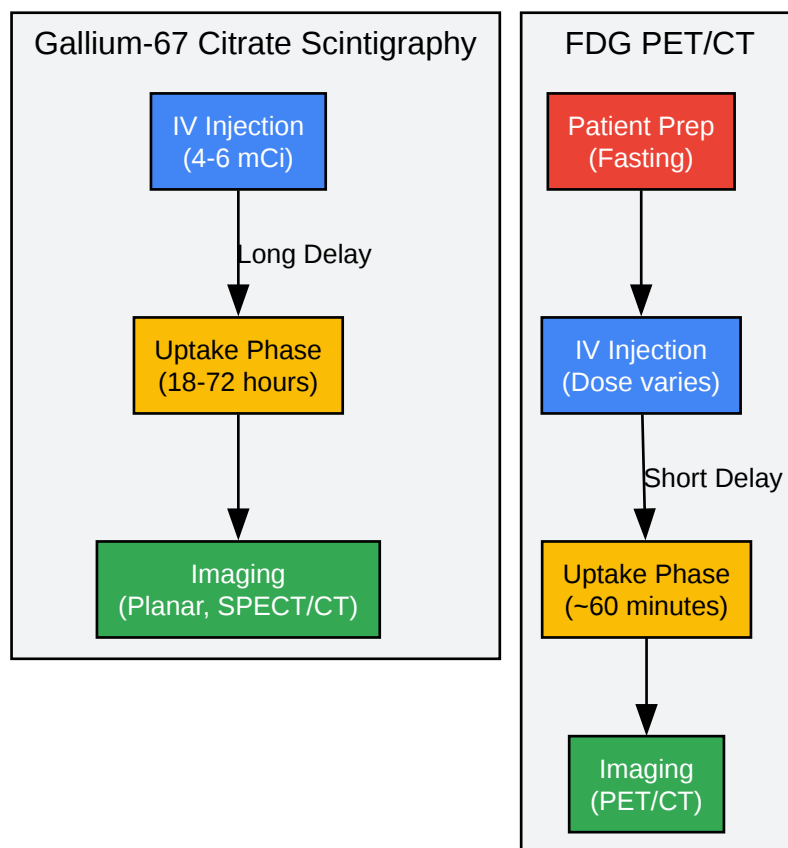
Imaging Acquisition:

- Imaging is typically performed 60 minutes after FDG injection to allow for tracer distribution and uptake.
- A PET/CT scanner is used to acquire images. The CT component provides anatomical localization and attenuation correction for the PET data.
- Image acquisition usually covers the area from the skull base to the mid-thigh, but can be adjusted based on the clinical question.

Comparative Workflow: From Injection to Interpretation

The following diagram illustrates the typical workflow for each imaging modality, highlighting the key differences in timing and procedure.

Comparative Imaging Workflow



[Click to download full resolution via product page](#)

Comparative Imaging Workflow

Conclusion: Selecting the Right Tool for the Job

Both Gallium-67 citrate and FDG PET are valuable tools for imaging inflammation in vivo, each with a distinct profile of advantages and disadvantages.

Gallium-67 citrate, while hampered by a long imaging delay, suboptimal image quality, and higher radiation dose, remains a viable option in specific scenarios, particularly for spinal osteomyelitis.[9] Its historical significance and continued use in certain contexts underscore its foundational role in nuclear medicine.

FDG PET, on the other hand, has largely become the preferred modality for inflammation imaging due to its superior image resolution, shorter study duration, and higher sensitivity in many inflammatory conditions such as fever of unknown origin and sarcoidosis.[1][2][3][7][8] However, its lack of specificity, as increased uptake can be seen in malignancy and post-surgical changes, remains a key consideration.

Ultimately, the choice between Gallium-67 citrate and FDG PET should be guided by the specific clinical or research question, the suspected type and location of inflammation, and the available resources. This guide provides the foundational data and protocols to empower researchers and clinicians to make an informed decision, ensuring the optimal imaging strategy for their specific needs.

Need Custom Synthesis?

BenchChem offers custom synthesis for rare earth carbides and specific isotopic labeling.

Email: info@benchchem.com or [Request Quote Online](#).

References

- 1. Fever of unknown origin: prospective comparison of [18F]FDG imaging with a double-head coincidence camera and gallium-67 citrate SPET - PubMed [pubmed.ncbi.nlm.nih.gov]
- 2. An update on the role of 18F-FDG-PET/CT in major infectious and inflammatory diseases - PMC [pmc.ncbi.nlm.nih.gov]
- 3. 18F-FDG PET and PET/CT in Fever of Unknown Origin | Journal of Nuclear Medicine [jnm.snmjournals.org]
- 4. Comparison of 18F-FDG PET/CT and 67Ga-SPECT for the diagnosis of fever of unknown origin: a multicenter prospective study in Japan - PubMed [pubmed.ncbi.nlm.nih.gov]
- 5. Comparative evaluation of 18F-FDG PET and 67Ga scintigraphy in patients with sarcoidosis - PubMed [pubmed.ncbi.nlm.nih.gov]
- 6. Direct Comparison of 67Ga-Scintigraphy and Fluorodeoxyglucose Positron Emission Tomography for the Evaluation of Cardiac Sarcoidosis - PMC [pmc.ncbi.nlm.nih.gov]
- 7. Comparison of 18F-FDG and 67Ga-citrate in sarcoidosis imaging - PubMed [pubmed.ncbi.nlm.nih.gov]
- 8. login.medscape.com [login.medscape.com]

- 9. researchgate.net [researchgate.net]
- 10. What is the mechanism of Gallium Citrate Ga-67? [synapse.patsnap.com]
- 11. Mechanism of gallium-67 accumulation in inflammatory lesions - PubMed [pubmed.ncbi.nlm.nih.gov]
- 12. Assessing cardiovascular infection and inflammation with FDG-PET - PMC [pmc.ncbi.nlm.nih.gov]
- 13. snmmi.org [snmmi.org]
- 14. Gallium Scan - StatPearls - NCBI Bookshelf [ncbi.nlm.nih.gov]
- 15. Scintigraphic Diagnosis of Inflammation and Infection | Radiology Key [radiologykey.com]
- 16. Procedure guideline for gallium scintigraphy in inflammation - ProQuest [proquest.com]
- To cite this document: BenchChem. [A Head-to-Head Battle in Inflammation Imaging: Gallium Citrate vs. FDG PET]. BenchChem, [2025]. [Online PDF]. Available at: [https://www.benchchem.com/product/b10776400#gallium-citrate-versus-fdg-pet-for-imaging-inflammation-in-vivo]

Disclaimer & Data Validity:

The information provided in this document is for Research Use Only (RUO) and is strictly not intended for diagnostic or therapeutic procedures. While BenchChem strives to provide accurate protocols, we make no warranties, express or implied, regarding the fitness of this product for every specific experimental setup.

Technical Support: The protocols provided are for reference purposes. Unsure if this reagent suits your experiment? [[Contact our Ph.D. Support Team for a compatibility check](#)]

Need Industrial/Bulk Grade? [Request Custom Synthesis Quote](#)

BenchChem

Our mission is to be the trusted global source of essential and advanced chemicals, empowering scientists and researchers to drive progress in science and industry.

Contact

Address: 3281 E Guasti Rd
Ontario, CA 91761, United States
Phone: (601) 213-4426
Email: info@benchchem.com

