

Application Note: High-Resolution Delayed Phase MRI of Liver Metastases Using Mangafodipir Trisodium

Author: BenchChem Technical Support Team. **Date:** April 2026

Compound of Interest

Compound Name: Mangafodipir trisodium [vandf]

Cat. No.: B10752371

[Get Quote](#)

Introduction & Mechanistic Grounding

The detection and characterization of sub-centimeter hepatic lesions remain a critical challenge in the staging of gastrointestinal malignancies, particularly colorectal and pancreatic adenocarcinomas[1]. While extracellular gadolinium-based contrast agents are useful for dynamic vascular imaging, they often fall short in distinguishing small metastases from background parenchyma.

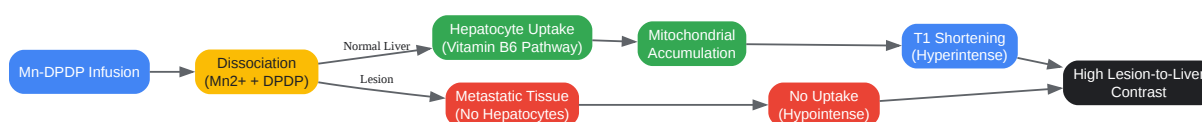
Mangafodipir trisodium (Mn-DPDP, commercially known as Teslascan) is a hepatocyte-specific MRI contrast agent engineered to overcome this limitation. The active paramagnetic component, the Mn^{2+} ion, possesses five unpaired electrons that produce profound T1 relaxation, resulting in marked signal enhancement on T1-weighted images[2].

The Causality of Contrast: Cellular Uptake vs. Exclusion

The diagnostic power of Mn-DPDP relies on a fundamental biological divergence between normal tissue and metastatic tumors. Following intravenous administration, the Mn-DPDP chelate slowly dissociates. The free manganese is actively transported into normal hepatocytes

via a mechanism closely resembling the vitamin B6 transport pathway, where it subsequently accumulates within the mitochondria[2][3].

Conversely, metastatic lesions (being of non-hepatocellular origin) completely lack the functional cellular machinery required to internalize Mn^{2+} [4]. Because the normal liver parenchyma becomes intensely bright (hyperintense) while the metastases remain dark (hypointense), the lesion-to-liver contrast-to-noise ratio is drastically amplified[2][4].



[Click to download full resolution via product page](#)

Cellular mechanism of Mn-DPDP contrast enhancement in normal liver versus metastatic lesions.

The Logic of the "Delayed Phase"

Unlike extracellular agents that require precise, second-by-second timing to capture arterial and portal venous phases, Mn-DPDP is optimized for delayed phase imaging.

- Early Delayed Phase (15–30 minutes): Maximum intracellular accumulation of manganese in the normal liver occurs approximately 15 to 30 minutes post-infusion[2][4]. At this plateau, the contrast between the enhanced normal liver and the unenhanced metastasis is typically at its peak[3].
- Late Delayed Phase (2–24 hours): While peak enhancement occurs early, imaging at 2 hours (and historically up to 24 hours) capitalizes on differential washout rates. Normal liver parenchyma slowly begins to clear the contrast via biliary excretion, but compressed normal hepatocytes at the tumor periphery often retain the contrast longer. This delayed washout creates a highly conspicuous hyperintense rim around the metastasis, highlighting sub-centimeter lesions that might have been obscured by partial volume effects during peak enhancement[5][6][7].

Quantitative Enhancement Profiles

To facilitate rapid clinical decision-making, the expected signal behaviors of various hepatic lesions under Mn-DPDP enhancement are summarized below^{[3][4][7]}:

Lesion Type	Cellular Origin	Mn-DPDP Uptake	Early Delayed Phase (15-30 min)	Late Delayed Phase (2-24 hr)
Normal Liver	Hepatocellular	High	Markedly Hyperintense	Iso/Hyperintense (Washout begins)
Metastasis	Non-hepatocellular	None	Hypointense	Hypointense (High contrast)
HCC	Hepatocellular	Variable	Heterogeneous Hyperintense	Heterogeneous Washout
FNH	Hepatocellular	High	Iso/Hyperintense	Iso/Hyperintense
Hemangioma	Non-hepatocellular	None	Hypointense	Hypointense

Standardized Experimental Protocol

Self-Validating Design: This protocol is inherently self-validating. The baseline unenhanced scan serves as the negative control, while the normal liver parenchyma acts as an internal positive control for Mn-DPDP uptake. If the background liver fails to exhibit a quantifiable T1 signal increase post-infusion, it indicates compromised infusion delivery, biliary obstruction, or severe hepatocellular failure, thereby invalidating the delayed phase diagnostic window.

Phase I: Patient Preparation & Baseline Control

- **Fasting:** Advise the patient to fast for at least 6 hours prior to the study. **Causality:** Fasting stabilizes blood glucose levels and prevents premature gallbladder contraction, ensuring stable biliary dynamics for optimal contrast retention^[1].

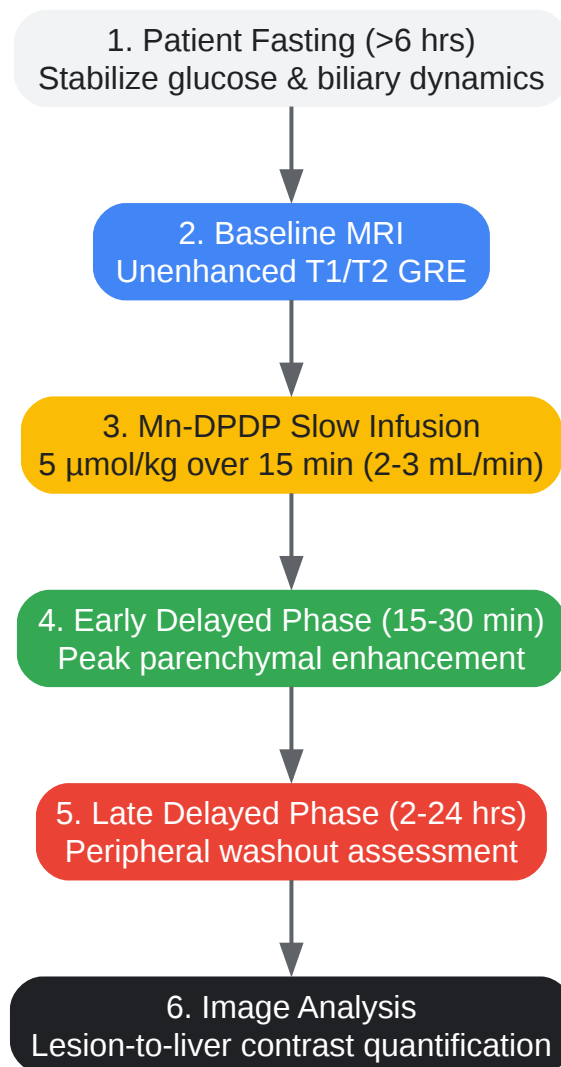
- Baseline Imaging: Acquire unenhanced T1-weighted (in-phase and out-of-phase) and T2-weighted 2D/3D gradient-echo (GRE) breath-hold sequences[1]. These images establish the baseline signal intensity required to quantify post-contrast T1 shortening.

Phase II: Contrast Preparation and Infusion

- Dosing: Prepare Mn-DPDP at a standard dose of 5 $\mu\text{mol/kg}$ body weight (approximately 0.5 mL/kg of a 0.01 M solution)[1][8].
- Administration: Administer via a slow IV infusion over 15 minutes (rate of 2–3 mL/min)[4][8].
 - Causality: A slow infusion is critical. Rapid bolus injection can cause transient adverse effects (e.g., flushing, palpitations) and may prematurely saturate the vitamin B6-like transport receptors on hepatocytes, reducing the total intracellular accumulation of manganese[4][8].

Phase III: Delayed Phase Image Acquisition

- Early Delayed Phase (15–30 min post-infusion): Acquire T1-weighted breath-hold FLASH or SGE (Spoiled Gradient-Echo) sequences[3][6]. This window captures the absolute peak of parenchymal enhancement, providing the highest global sensitivity for metastatic detection[2][4].
- Late Delayed Phase (2 hours post-infusion): Repeat the T1-weighted GRE sequences.
 - Causality: While 24-hour imaging provides the theoretical maximum for peripheral washout assessment, a 2-hour delay is the most practical clinical window[6]. It provides sufficient time for the background liver signal to begin normalizing, isolating the retained contrast in compressed peritumoral hepatocytes to reveal sub-centimeter lesions[5][6].



[Click to download full resolution via product page](#)

Standardized clinical workflow for delayed phase liver MRI using Mangafodipir trisodium.

References

- Diagnostic Accuracy of Rim and Segmental MRI Enhancement of Colorectal Hepatic Metastasis After Administration of Mangafodipir Trisodium | AJR.American Journal of Roentgenology.
- New MR techniques for the detection of liver metastases - PMC.
- Characterization of focal liver lesions: Use of mangafodipir trisodium (MnDPDP)-enhanced MR images.Turkish Journal of Gastroenterology.
- Imaging of liver metastases: MRI - SciSpace.SciSpace.
- Detection of Liver Metastases from Adenocarcinoma of the Colon and Pancreas: Comparison of Mangafodipir Trisodium-Enhanced Liver MRI and Whole-Body FDG PET |

AJR.American Journal of Roentgenology.

- Comparison of Mangafodipir Trisodium- and Ferucarbotran-Enhanced MRI for Detection and Characterization of Hepatic Metastases in Colorectal Cancer Patients - AJR Online.American Journal of Roentgenology.
- Contrast agents used in MR imaging of the liver - Diagnostic and Interventional Radiology.Diagnostic and Interventional Radiology.
- Mangafodipir trisodium-enhanced magnetic resonance imaging for evaluation of pancreatic mass and mass-like lesions - PMC.

Need Custom Synthesis?

BenchChem offers custom synthesis for rare earth carbides and specific isotopic labeling.

Email: info@benchchem.com or [Request Quote Online](#).

Sources

- 1. ajronline.org [ajronline.org]
- 2. ajronline.org [ajronline.org]
- 3. scispace.com [scispace.com]
- 4. turkjgastroenterol.org [turkjgastroenterol.org]
- 5. New MR techniques for the detection of liver metastases - PMC [pmc.ncbi.nlm.nih.gov]
- 6. ajronline.org [ajronline.org]
- 7. dirjournal.org [dirjournal.org]
- 8. Mangafodipir trisodium-enhanced magnetic resonance imaging for evaluation of pancreatic mass and mass-like lesions - PMC [pmc.ncbi.nlm.nih.gov]
- To cite this document: BenchChem. [Application Note: High-Resolution Delayed Phase MRI of Liver Metastases Using Mangafodipir Trisodium]. BenchChem, [2026]. [Online PDF]. Available at: [<https://www.benchchem.com/product/b10752371/docs#application-note-high-resolution-delayed-phase-mri-of-liver-metastases-using-mangafodipir-trisodium>]

Disclaimer & Data Validity:

The information provided in this document is for Research Use Only (RUO) and is strictly not intended for diagnostic or therapeutic procedures. While BenchChem strives to provide

accurate protocols, we make no warranties, express or implied, regarding the fitness of this product for every specific experimental setup.

Technical Support: The protocols provided are for reference purposes. Unsure if this reagent suits your experiment?

Need Industrial/Bulk Grade? [Request Custom Synthesis Quote](#)

BenchChem

Our mission is to be the trusted global source of essential and advanced chemicals, empowering scientists and researchers to drive progress in science and industry.

Contact

Address: 3281 E Guasti Rd

Ontario, CA 91761, United States

Phone: (601) 213-4426

Email: info@benchchem.com

[Contact our Ph.D. Support Team for a compatibility check](#)